

# The Medical Advisor

Your Trusted Science-backed Resource for Health, Nutrition, Beauty, and Lifestyle since 2012

[HOME](#)[E-SHOP](#)[COVID-19](#)[CANCER](#)

## Fenbendazole Cancer Success Stories: 119 Case Reports Compilation (March 2025 Edition)



By Editorial Team - March 25, 2025

### Contents:

- Editor's Preface
- Introduction
- **Fenbendazole** Case Series Compilation (alphabetical)
  1. Appendix Cancer
  2. Breast Cancer Success Stories (11 cases)
  3. Brain Cancer (Glioblastoma)
  4. Bile Duct Cancer (Cholangiocarcinoma)
  5. Bladder Cancer Success Stories (5 cases)
  6. Cervical Cancer
  7. Colorectal Cancer (11 cases)
  8. Esophageal and Stomach cancer
  9. Endometrial Cancer (4 cases)
  10. Gastric (Stomach) cancer (3 cases)
  11. Head and Neck Cancer (3 cases)
  12. Kidney Cancer Case Series (8 cases)
  13. Liver Cancer (2 cases)
  14. Lung Cancer (11 cases)
  15. Leukemia (2 cases)
  16. Lymphoma (4 cases)
  17. Melanoma (Skin Cancer)
  18. Multiple Myeloma
  19. Myelodysplastic Syndrome
  20. Oral Cancer

23. Prostate Cancer (15 cases)
24. Salivary Gland Cancer
25. Sarcoma (2 cases)
26. Skin Cancer (8 cases)
27. Throat Cancer
28. Thymus cancer
29. Tongue Cancer
30. Turbo Cancer
31. Uterine cancer

- Conclusion

## Editor's Preface

We began this article with just a handful of cases, but it has since expanded to include over 100 case reports from diverse sources.

### **“The cure for cancer? It all started with a single case study.”**

Let's start with the mainstream perspective—the one you've likely heard from conventional cancer specialists or major media outlets:

- *We need larger, high-quality studies before making formal recommendations.*
- *There is no evidence that **fenbendazole** works, or its effectiveness is unproven.*
- *There are no randomized controlled trials on **fenbendazole**.*
- *This is 'false hope.' If something sounds too good to be true, it probably is.*

You may have discovered this article through a social media link rather than mainstream news or major search engines. Why is that?

Unlike traditional platforms, social media allows the rapid sharing of niche or underrepresented stories—giving content like this a chance to reach those who might otherwise miss it.

When diagnosed with cancer, most people rely on discussions with family members and doctors. However, they often encounter conflicting recommendations—some professionals support exploring **fenbendazole**, while others strongly oppose it.

So, what's fact and what's fiction? The answer depends on science and research. However, science can be biased, manipulated, or selectively presented to fit a particular narrative. That's

## The Case for a Precautionary Approach

According to *The Cochrane Review's* editor-in-chief, Karla Soares-Weiser ([source](#)):

*"Lack of evidence of effectiveness is not evidence that the interventions are ineffective... Waiting for strong evidence is a recipe for paralysis. Public health officials must take measured gambles, based on circumstantial evidence from the reviewed studies and other sources. When protecting the public from harm, they must act even when evidence is uncertain (or not of the highest quality), particularly when the harms and costs of such action are likely limited."*

Even if the chance of **fenbendazole** helping is small, individuals have the right to explore it as an option.

Dr. John Campbell, a health educator with over 3 million YouTube followers, shared ([video](#)) a compelling perspective in his video on **fenbendazole** and ivermectin for cancer:

*"People have the right to try. They could try these drugs... and we could track them over time. We could build national cohorts of tens of thousands of patients in no time... then hand it over to statisticians to analyze the data and uncover the mathematical truth. This could be done, and in my view, it should be done."*

## Real Stories, Real Hope

The testimonials you are about to read are from individuals who have bravely shared their experiences in the hope of inspiring and uplifting others. These are raw, unfiltered accounts—not peer-reviewed studies—but they offer insights that may be valuable to those searching for options.

It's important to acknowledge that the **Fenbendazole** protocol is not a universal cancer cure.

We are not here to advocate for or against any treatment—whether conventional (surgery, chemotherapy, radiation, immunotherapy) or alternative approaches. Our focus is on **effective and safe** strategies that may offer hope and improved outcomes.

This article is not meant to be your final guide, but rather a step in your journey toward better health. We encourage you to seek out additional resources, ask questions, and explore all available options.

## A Final Word of Encouragement

If you have stage 4 cancer, **don't lose hope**. Your story could be the next inspiring success.

Instead of relying solely on large-scale studies, case reports focus on individuals—allowing people to directly assess how specific interventions affect their unique health profiles. As Snyder told *The Epoch Times*,

*“We are all different, and now we can collect a lot of data on a single person or a few individuals to make very specific recommendations.”*

In the end, science evolves. Until then, the right to try belongs to you.

## Introduction

**Fenbendazole**, often referred to as FenBen, is an anthelmintic medication initially developed to eliminate roundworms and pinworms in animals and humans.

**Fenbendazole** is a broad spectrum anthelmintic used against gastrointestinal parasites including: giardia, roundworms, hookworms, whipworms, the tapeworm genus *Taenia* (but not effective against *Dipylidium caninum*, a common dog tapeworm), pinworms, *aelurostrongylus*, paragonimiasis, strongyles, and strongyloides that can be administered to sheep, cattle, horses, fish, dogs, cats, rabbits, most reptiles, freshwater shrimp tanks as planaria and hydra treatments, as well as seals.

Common brand names include Pancur, Panacur C and Safe-Guard.

*Note: In everyday conversations within the **fenbendazole** communities, you might encounter **Fenbendazole** referred to as Phenbendazole, Panacur or SafeGuard. This interchangeability is representative of the common use of the trademarked name; it signifies a consensus within these circles that these terms denote the same medication. **Fenbendazole** is the active ingredient in all these products. Molecular formula for **fenbendazole** is  $C_{15}H_{13}N_3O_2S$ .*

However, it is also being used by humans in a cancer treatment method known as the **Joe Tippens Fenbendazole Protocol**.

Although first introduced in 1961, it wasn't until 2009 that FenBen's potential as a cancer treatment was discovered during a **glioblastoma (GBM) study at Johns Hopkins University**. Since then, numerous case reports have demonstrated FenBen's effectiveness in treating various cancers, including lung, kidney, liver, breast, prostate, melanoma, bone, ovary, colon, and brain tumors.

*Related: [Top 10 Cancer Fighting Supplements](#)*

222mg 3x per week	222mg/day (6 days a week)	444mg/day (6 days a week)	888mg or 1000mg/day (6 days a week)
Cancers in remission Strong family history Genetic predisposition Prophylaxis	Starting dose for most cancers Weight < 200lb (fenbendazole.org)	mRNA Turbo Cancer Aggressive Cancers Stage 4 Weight 200+ lb	Extensive metastatic disease Extremely poor prognosis
Check liver function & kidney function	Check liver function & kidney function	Check liver function & kidney function	Check liver function & kidney function
Joe Tippens Protocol: 222 mg Fenbendazole 3 days on, 4 days off (Panacur C) Vitamin E 800 IU/day Curcumin 600mg/day CBD oil 25mg/day	Taken with/after meal Milk Thistle 250mg twice a day with food (liver support)	Taken with/after meal Milk Thistle 250mg twice a day with food (liver support)	Max 30-50mg/kg/day for 5 days (very rarely used in this dose range)

Fenbendazole dosage for Cancer in Humans

## Fenbendazole Case Series Compilation

The following success stories were gathered from various web and social media sources, providing anecdotal, crowd-sourced information.

The list of fenbendazole and cancer case reports below is organised alphabetically by cancer type.

### 1. Appendix Cancer

**Judy Howell** 23 mins ago ♥ Liked by 2nd Smartest Guy in the World

I used the fenbendazole protocol to fight my very rare appendix cancer in 2023. Doctors told me it would not work and not to bother but I did it anyway. A year out and I'm cancer free. Will not be "cured" for five years, but I'm alive and I believe it was due to fenbendazole.

♥ LIKED (1) 🗨 REPLY 📤 SHARE ⋮

Source: <https://substack.com/home/post/p-155091883>

### 2. Breast Cancer Success Stories (11 Cases)

Case 11:

**IVERMECTIN and MEBENDAZOLE Testimonial - 75 year old patient with Breast cancer 10 years ago, has 5 new breast masses. They almost completely disappear after 4 months on protocol!**

Some of the results I get are absolutely jaw dropping.  
This one is a "must see".

**STORY:**

75 year old patient had **breast cancer** 10 years ago

recently developed multiple breast masses and neck lymph nodes up to 3.6cm.

**"I do not wish to be treated by the traditional medical system, after a past breast cancer episode and also learning from the COVID pandemic"**

Fair enough.

We started a protocol in October 2024:

**Ivermectin 1mg/kg/day**

**Mebendazole 1000mg/day**

RESULTS after 4 months on the Makis Ivermectin Cancer Clinic Protocol:

Patient: **"The comparison is almost unbelievable!"**

**1.6cm right breast lesion - gone**

**1.2cm right breast lesion - now 0.9cm**

**3.6x2.9cm left breast lesion, possible intramammary lymph node - gone**

**1.7cm left breast lesion - gone**

**2.9x2.3cm left breast lesion - gone**

**disappeared!"**

No biopsy. No surgery. No chemo. No radiation.  
No other explanation.

These breast masses weren't that small either!

When I post these testimonials and the patient also took chemo, many people like to claim the chemo did all the work (and Ivermectin doesn't work).

There was no chemo in this case. No radiation. No other treatment of any kind.

### **Case 10: 35 year old woman with Stage 4 Breast Cancer (triple positive) to lungs and bones**

Dr. William Makis [shared on X](#) (Twitter) in February 2025:

IVERMECTIN and MEBENDAZOLE Testimonial with TURBO CANCER

FROM THE BRINK: 35 year old Stage 4 Breast Turbo Cancer patient with "little time left to live" to "NO ACTIVE DISEASE" - the miracle PET/CT scan at 6 months!

This was one of my first Ivermectin Clinic patients: 35 years old US woman with Stage 4 Breast Cancer to lungs and bones

Initially diagnosed in Nov 2023 with triple positive breast cancer.

"We suspect that she may have a COVID-19 vaccine induced turbo cancer as she received both doses of the vaccine and a booster. Her husband, 36 years old, who received the same vaccines as her at the same time, was diagnosed with testicular cancer"

2024: "We were recently informed that her cancer is resistant to treatment and very aggressive". It is confirmed to have metastasized to her lungs, sternum and spine"

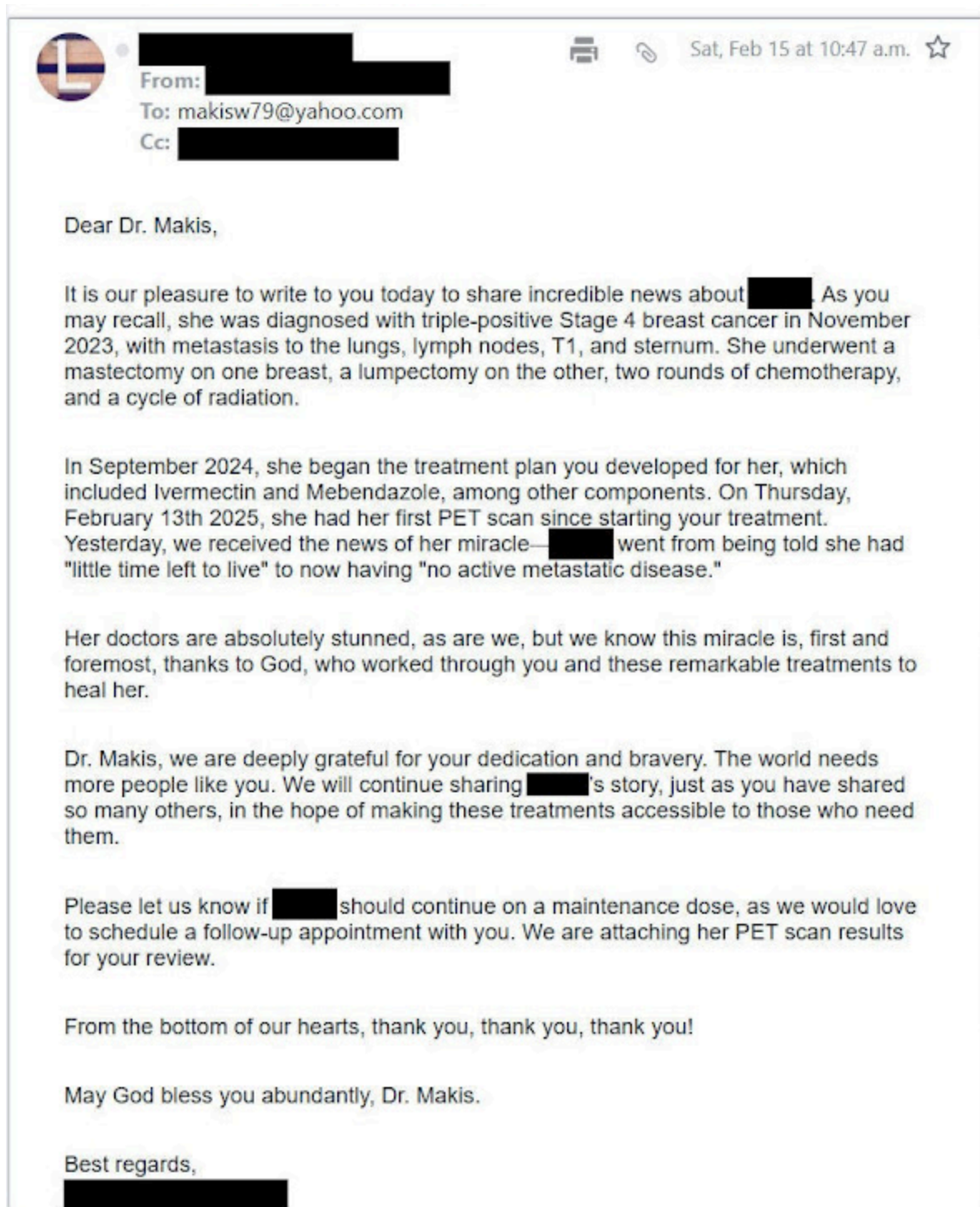"Her Oncologists have informed her that she has little time left and they are not open to trying any of the drugs you have mentioned like Ivermectin".

- Ivermectin 1mg/kg/day escalating dose to 2mg/kg/day
- Mebendazole 1500mg/day

Why am I aggressive in my dosing? Have a look at the follow-up PET/CT scan done 6 months into Ivermectin/Mebendazole.

Impression:

"Excellent treatment response with interval left mastectomy as well as complete resolution of FDG avid bone metastasis and bilateral hilar FDG avid lymph nodes that were present on prior exam. No findings to suggest active malignant disease at this time".



metastasis when compared to prior study. Another metastatic bone lesion at T1 has also completely resolved. No suspicious FDG avid bone lesions at this time.

**IMPRESSION:**

Excellent treatment response with interval left mastectomy as well as complete resolution of FDG avid bone metastasis and bilateral hilar FDG avid lymph nodes that were present on prior exam. **No findings to suggest active malignant disease at this time.**

Signed Electronically By: Dr. [REDACTED] - 2/14/2025

If you are a physician, to speak to a radiologist or for all your radiology needs, please call our Physician Connect line at [REDACTED] and press 1 to speak to a radiologist.

**Case 9: Stage 4 metastatic breast cancer (Jan 2025 Update)**

Carla shared on [X/Twitter](#):

"Diagnosed Stage 4 metastatic breast cancer in November of 2022. Started **Fenbendazole** right away and also switch it up one week a month with ivermectin. I've been cancer free for over a year!"

**Case 8: IVERMECTIN and MEBENDAZOLE\* Testimonial - 69 year old USA Stage 4 Breast Cancer patient with metastases to liver and bones on Enhertu (December 2024)**

Dr William Makis shared on [X/Twitter](#):

IVERMECTIN and MEBENDAZOLE\* Testimonial - 69 year old USA Stage 4 Breast Cancer patient with metastases to liver and bones on Enhertu

69 year old woman with Stage 4 Breast Cancer to liver and bones

Had 2 treatments of Enhertu with Ivermectin 36mg and Mebendazole 500mg a day for 3 weeks

CEA dropped from 148.4 to 83.9 (that's a 43% drop!!)

What is Enhertu?

HER2 protein on their cell surface"

Grok will tell you that it wasn't Enhertu that did this:

"In summary, while there is some indication from patient experiences that Enhertu might lead to reduced CEA levels in some individuals, this is not a guaranteed or direct effect of the drug." That 43% drop in tumor marker CEA was due to the Ivermectin and Mebendazole addition to the treatment regimen.

I share these to show what optimizing Cancer Treatment looks like (especially in Stage 4 Cancer patients). This is cutting edge work not being done at any Cancer Centre in the United States or Canada.

\*Note: Although technically mebendazole is not the same as **fenbendazole**, both mebendazole and **fenbendazole** are part of a larger group of drugs known as benzimidazole\*, which are anthelmintic drugs (i.e., drugs that kill parasitic worms).

*\*The class of drugs known as benzimidazoles includes **fenbendazole**, mebendazole, albendazole and flubendazole.*

**Fenbendazole** and mebendazole are similar in that they both eliminate parasitic worms, but there is a difference. Mebendazole is approved for human consumption by the FDA, while **fenbendazole** is only approved for veterinary use and has not been approved for human use.

Mebendazole is the form that is approved for human use while **fenbendazole** is approved for veterinary use. The main difference is the cost. Mebendazole is expensive ~\$450 per pill (two pills of mebendazole cost just \$4 in the UK.), while **fenbendazole** is inexpensive ~48 cents per 222 mg free powder dose (Williams, 2019). Albendazole is the form used to treat intestinal parasites in India and these cost 2 cents per pill.

While most of the pre-clinical research uses mebendazole, probably because it is the FDA-approved-for-humans form of **fenbendazole**, virtually most of the self-treating clinical reports involve the use of **fenbendazole**.


makismd.substack.com/p/ivermectin-and-mebendazole-testimonial-430

**COVID INTEL** Dashboard

### IVERMECTIN and MEBENDAZOLE Testimonial - 69 year old USA Stage 4 Breast Cancer patient with metastases to liver and bones on Enhertu

DR. WILLIAM MAKIS MD  
DEC 29, 2024 - PAID

43 3 2 Share



Re: ALTERNATIVE MEDICINE PROTOCOL (Dr.Makis) Yahoo/04 - TES... ☆

From: [Redacted] To: William Makis Sun, Dec 15 at 10:12 a.m. ☆

Hello Dr. Makis:

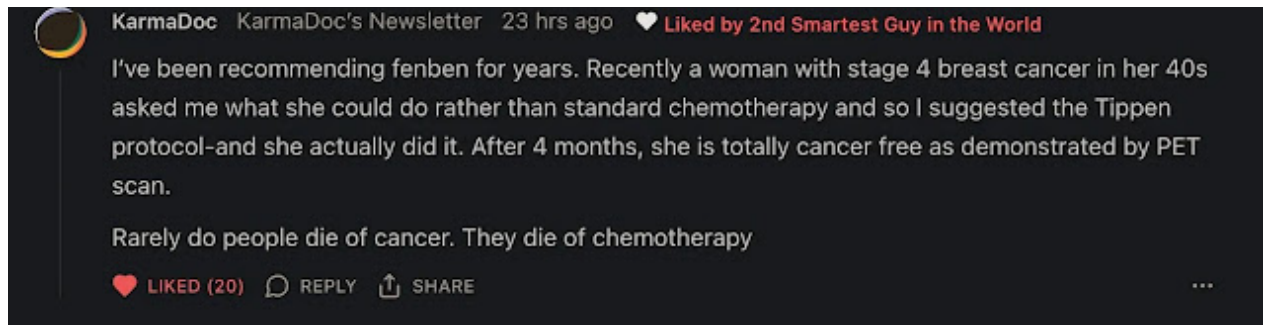
IVM 3 X12 mg per day w/food = 36 mg & Mebendazole 500 mg per day. No, I have not taken Milk Thistle.

I have an ultrasound scheduled on 12/26/24 from gastroenterologist to see if there is swelling in liver and next enhertu infusion 12/30/24.

On a positive note, my CEA level last blood work, 12/9 was @ 83.9; 10/30 @148.8 & 10/3 @ 164.8.

Thank you,  
[Redacted]

Case 7:



source: <https://substack.com/home/post/p-155091883>

### Case 6: IVERMECTIN, FENBENDAZOLE and LACTOFERRIN Testimonial - 70 year old Stage 4 Breast Cancer patient with bone and brain metastases (December 2024)

Dr William Makis shared on [X/Twitter](#):

IVERMECTIN, FENBENDAZOLE and LACTOFERRIN Testimonial - (SPAIN) 70s year old Stage 4 Breast Cancer patient with bone and brain metastases sees dramatic improvements in Quality of Life!

70s year old Stage 4 Breast Cancer patient with bone and brain metastases.

Family reached out to me.

We started a protocol:

- **Ivermectin 1mg/kg/day**
- **Fenbendazole 444mg/day 6 days a week**
- **Lactoferrin 1000mg/day**



Sometimes it's the quality of life improvements you can see right away:


- *"Pain gradually decreasing"* (requiring less pain medications)
- *"Starting to get up and walk around the house"* - Increased mobility
- *"being able to sleep on her side, which she couldn't do before"*
- *"willing to do things"* (improved mood)
- *"she can get up alone from bed and sofa"* (improved strength)
- *"blood test results showing good improvements"* (improved blood work)

And my favorite:

• Re: Breast cancer metastatic in brain and bones Yahoo/04 - TES... ☆

---

  🖨️ 🔗 Wed, Dec 11 at 1:50 p.m. ☆

**From:**   
**To:** William Makis

Hi William, hope you and your family are well even all you're going through.


My mom is improving every day, she feels better, willing to do things, she can get up alone from bed and sofa, she is walking sometimes with the walker help and others alone some steps. We are very very happy with the improvements.

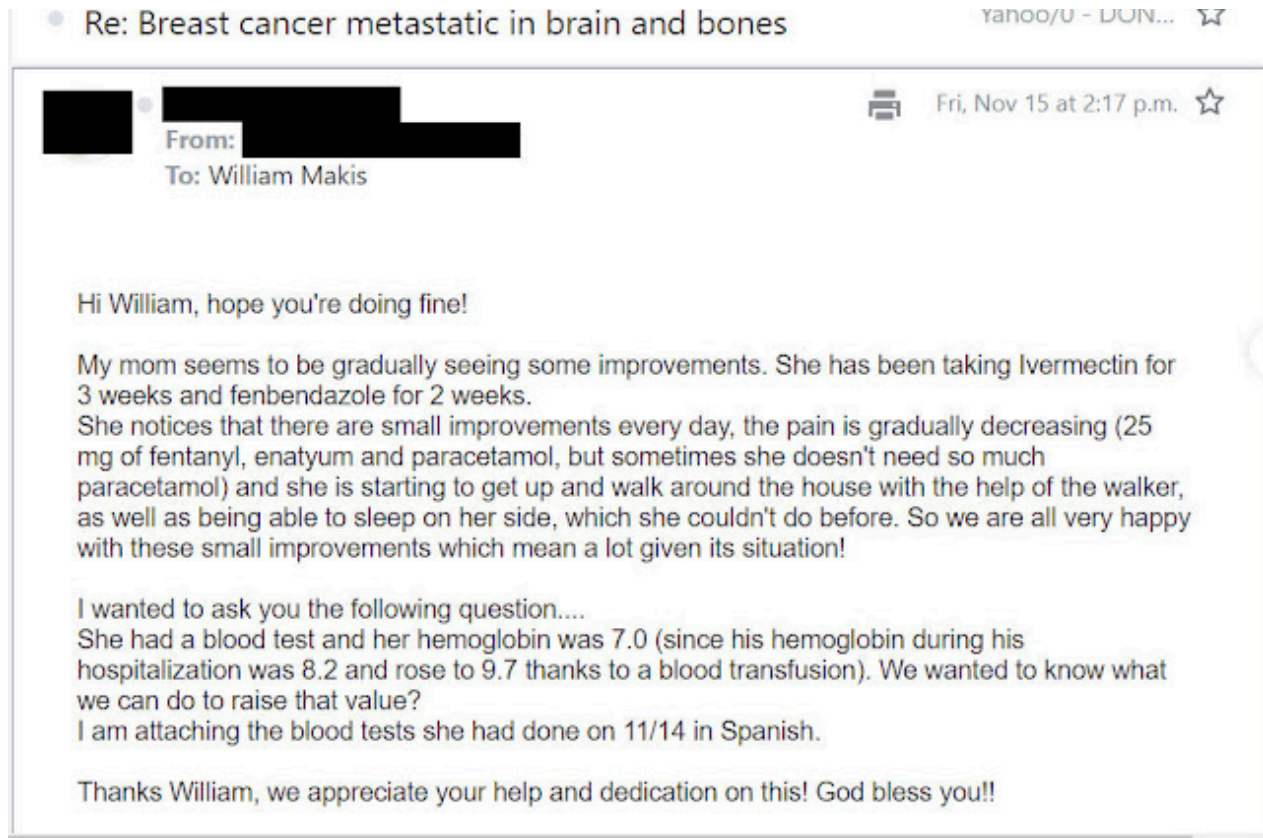
Today we received another blood test result and some values are showing good improvements, even with anemia. She is taking lactoferrin as you suggested.

Her oncologist was very surprised to see her well, with lucidity and with enough mobility (remember we're lying him about the treatment ;) )

He recommended her, for the next visit in one month, ZOMETA (zoledronic acid). What do you think about this? Would you recommend the administration of this drug?  
Do you have any additional information we can read and/or investigate?

Thanks William! I wish you all the best at this moment, you and your family are going through a lot right now and you do not deserve that! The truth will be known soon!  
I always have you in my thoughts wishing you the best.





### Case 5: July 2024 (Last Update)

I found a breast cancer lump in my left breast in 2016. I stupidly allowed my doctor to biopsy the lesion, which broke the capsule around it. This may have permitted the cancer to spread to the nodes, making me Stage 2 with three positive lymph nodes. The doctors had said the lump was too big to do a lumpectomy. I should have done cryotherapy to treat the nodule but chose instead to have a bilateral mastectomy with reconstruction in one procedure to avoid repeated MRIs and constant worry. After surgery, they recommended tamoxifen, chemo, and radiation. I refused it all and was treated with diet, DIM supplements, vitamin D, stress reduction, psychological counseling, and spiritual work.

In early 2022, I began to have a cough and shortness of breath. My chest x-ray showed a large right pleural effusion (fluid around my lung), and when it was sampled using a needle, it contained malignant breast cancer cells. My scans showed mediastinal lymph nodes (in the chest's center), a nodule in the right upper lung lobe, and a lymph node in each armpit.

To breathe, I was forced for a time to have the fluid around my lungs extracted with a needle every two weeks. This was despite using hyperbaric oxygen therapy, a detox supplement regimen, and other treatments, including green tea, vitamin C infusions, ozone therapy, high-

on arousal states. Instead, it works on frequencies using a complex computer algorithm program that can be used diagnostically and therapeutically. I also began daily ivermectin (IVM) and beta-carotene supplements.

Within four months of starting IVM, the fluid stopped forming around my lungs. My PET scan six months after beginning ivermectin showed no active cancer in any fluid, no nodule in the lung, and just a couple of lymph nodes that were below the active cancer metabolic threshold.

I then (stupidly) tapered the ivermectin dose to 30 mg twice a week. I was taking so many supplements and foods that I could not tell what was working. The pleural effusion recurred about three to four months after reducing the ivermectin. It was in my left lung this time, and the mediastinal lymph nodes reappeared. I had missed the importance of ivermectin in my overall treatment plan.

In August 2023, I visited the Hope 4 cancer clinic in Cancun, but it was an expensive disaster that did nothing to help me. I again started requiring weekly pleural taps and eventually needed a Pleurex catheter to drain the fluid daily. My left lung was my only normal lung after damage to my right lung in 2022 from the constant fluid and subsequent lung collapse.

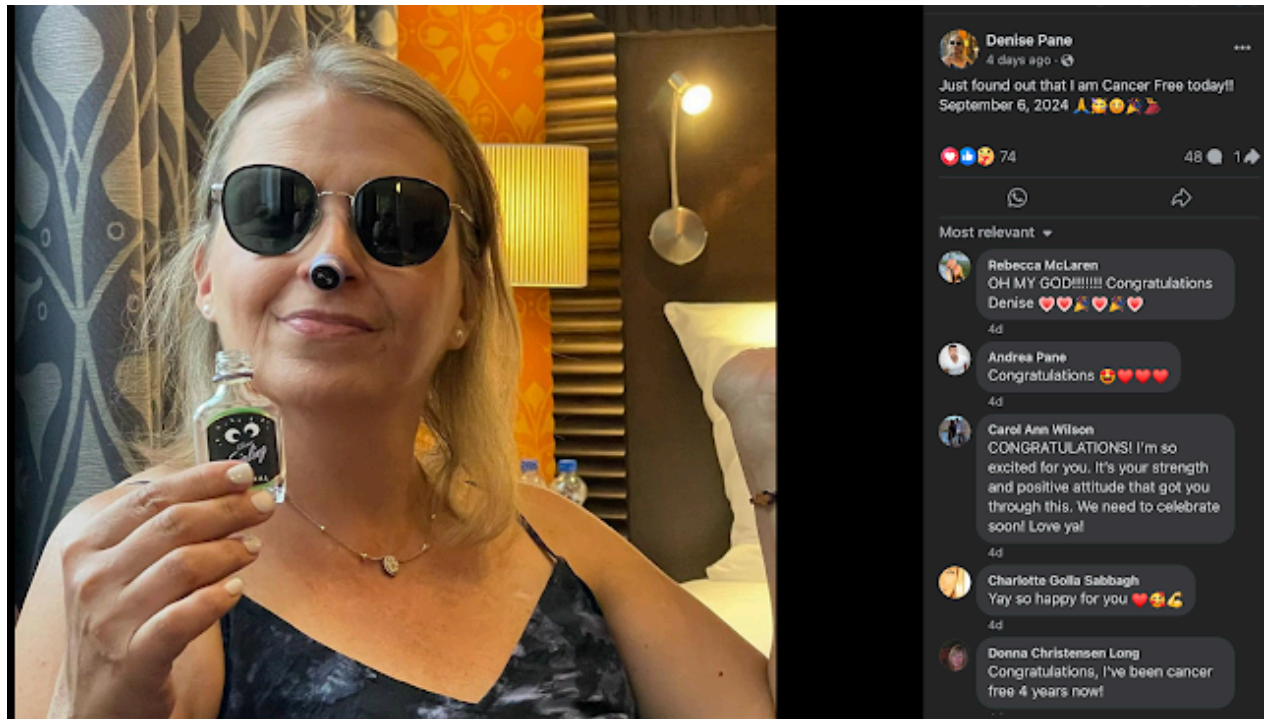From September 2023 until July 2024, I took 120mg of IVM daily plus **fenbendazole** 444mg daily. Six months later, fluid stopped forming around my left lung. However, I started developing teeth staining, and after about five months, my blood enzymes showed liver dysfunction. After a 10-day break from both medications and restarting them at lower doses, I felt better. My PET/CT scans in March 2024 and July 2024 showed no cancer metabolic activity and no evidence of cancer or lymph nodes anywhere, and my follow-up scans are planned for October 2024. I now take 45mg of ivermectin five days a week, none on the weekend, and **fenbendazole** 440 mg twice a week.

*Read More: [BREAST CANCER, IVERMECTIN, FENBENDAZOLE AND TIPS FOR OTHER CANCERS - DR KATRINA LEWIS](#)*

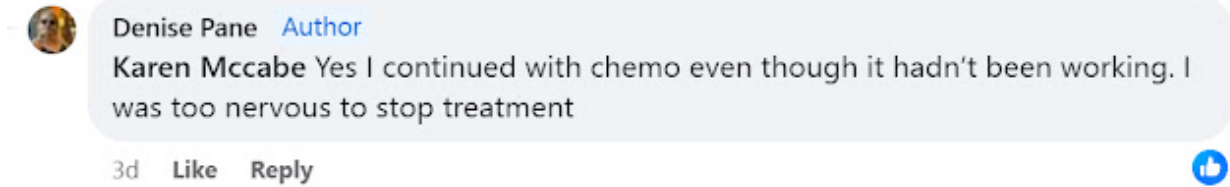
#### **Case 4: September 2024 (Last Update)**

"I had metastatic breast cancer that spread to my bones. I was in the hospital most of Jan/Feb of this year. Couldn't walk without assistance and was in excruciating pain" "I had heard about Fenben through a friend and decided to finally give it a try" "My markers were dropping and my

Sep.6, 2024: "Just found out that I am Cancer Free today!!"



Source: Facebook




## Recent Activity



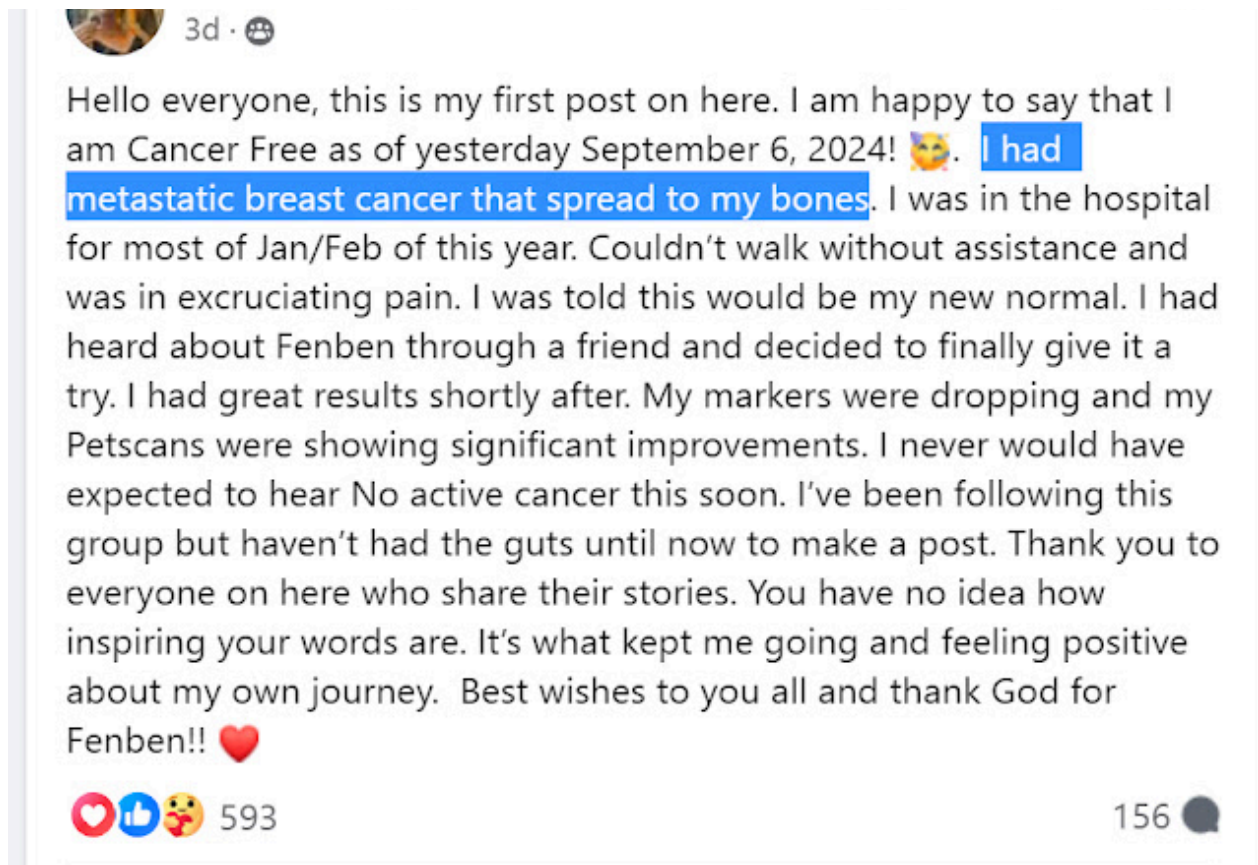
Denise Pane  replied to her own comment: "Selda Asan Congratulations to you for starting  $\square$ . I started the same way, with 222mg 3x's a week. Every two weeks or so I upped my days and dose. I had a slow start but had good results from early on. Every Petscan was better than the last. My markers kept dropping too. I wish you and everyone out there suffering with this, a great outcome.   $\square$ "

---



Denise Pane  replied to her own comment: "Patrice Marie I plan on continuing my same protocol- I may lower the dose to 1500mg. I got up to 1,750mg."

---



### Case 1: December, 2022

Condition: Stage 4 ER+PR+HER2- Metastatic Breast Cancer to bones

A friend told me about the Joe Tippens Protocol and ivermectin the day after I got my diagnosis for a third bout with breast cancer. I started both immediately. I saw my oncologist a week later. She added Faslodex, Kisqali, and Femara. She supported me added the JTP and the ivermectin. In 8 weeks I was in remission as measured by my CA2729. At week 11, a PET scan showed NED.

Which of the protocol components did you use? **Fenbendazole**, Curcumin, CBD/ cannabis Oil, Berberine, Other

Other supplements used: 12 mg ivermectin daily

Which conventional treatments did you do? Hormone therapy

### Case 2: March, 2022

weaker as the days went by. I felt this lump on the side of my breast and got it checked out right away. I received the news that I have stage 4 metastatic breast cancer Mets to lymph nodes, liver and bone In my upper shoulder.

### **Case 3: June, 2021**

Three years ago I received a lumpectomy, which is when the cancer gets removed from a part of the breast tissue. The surgery was successful and I was declared free of any cancer back then, till about two years later I was diagnosed with stage 4 breast cancer with Mets to lymph nodes, bones, and bone marrow. It basically spread all over my body. This was terrifying at the time and I felt there was no way to win this battle.

With no options left, I decided to go onto the Joe Tippens protocol, and followed it for a whole good year before I received my PET scan results stating that I am cancer free! And to make this even more insane to think of – I wasn't receiving any form of chemo or radiation ever during the recovery process, the only medication I consumed alongside following this protocol was hormone blockers.

I however got very sick in the beginning stages of using this protocol and started using Serrapeptase (an enzyme) along with it, which seems to have taken all side effects away. I gained my strength back and my blood tests were normalized on every account. After being only 6 months on the protocol more than half of my cancer disappeared. Here is a brief idea of what my protocol looked like:

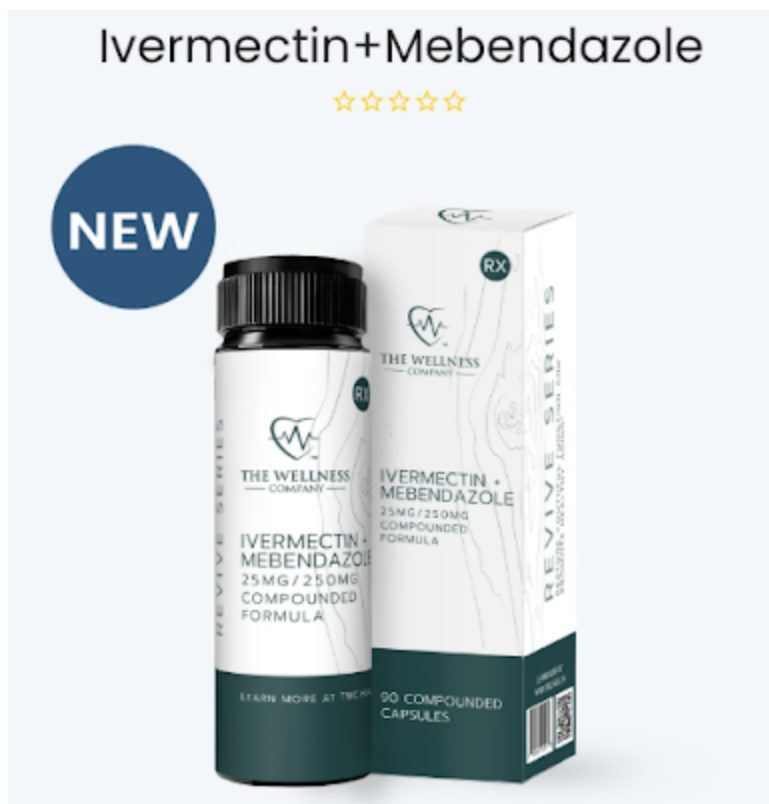- Serrapeptase (as I wake up)
- Fenben, Vit D and Vit K, Quercetin with Zinc (at noon)
- Turkey tail mushrooms & Letrozole (also at noon)
- RSO (before bedtime, but a very little amount)

I only removed refined sugars and corn syrup from my daily diet and other than that, I just continued with my activities of daily living. This combination of supplements along with the fenben really did the magic and I will continue to follow this lifestyle to prevent any evidence of disease to show up!

### **Video Testimonial of Breast Cancer (Triple Negative Breast Cancer) Recovery with Fenbendazole Protocol**



### The Wellness Company's Ivermectin and Mebendazole



Available on The Wellness Company's website: [Ivermectin and Mebendazole](#)

## 3. Brain Cancer Success Story (2 cases)

### Case 2

IVERMECTIN and FENBENDAZOLE Testimonial - 41 year old Canadian man with Grade 3 Oligodendroglioma Brain Cancer opts out of chemo & radiation - doing extremely well!

#### STORY:

41 year old Ontario man had an aggressive Grade 3 Oligodendroglioma that was mostly resected in early June 2024. After surgery, he opted out of chemo and radiation therapy.

Sep.2024 MRI showed "residual parenchymal tumoral component" 4.5x4.1x3.6cm.

We started an aggressive Makis Ivermectin Cancer Clinic Protocol: Ivermectin 1mg/kg/day increasing to 2mg/kg/day Fenbendazole 888mg/day

He had a follow-up MRI 3 months later:

RESULTS: The Radiologist couldn't find the residual tumor! From the patient: "Thank you so much. I don't know how else to put it. This is not a big deal...its THE deal. A cure for "terminal" brain cancer. The implications are mind-blowing and its sad so few people know about these options." "Keep up the good fight please!"

#### Case 1

Case sharing by Michelle Wright ([X/Twitter](#)):

*The reading of the results has been posted!! There is a whole lot that I DON'T understand, but I can understand enough to see that THERE HAS BEEN IMPROVEMENT!! I appreciate all of the prayers and well wishes! For anyone that isn't up to date- my Dad was diagnosed with Glioblastoma in April of this year. He had completed one full round of chemo and radiation, and at the beginning of August he was not well. I won't go into detail. However, I had been doing a lot of research and one of the AWESOME pages I found here was [@JohnDParody](#) I went with a protocol that I felt was best and got my Dad started on a journey with Ivermectin and Fenbendazole. He HAS continued his chemo treatments, but I 100% believe it has been that being used in combination with the Ivermectin and Fenben that has gotten him where he is today. I've been here, and I've watched him improve daily. I do not have pictures of the scans themselves, because they're not posted on the portal. But if anyone would like to compare it to any of his previous readings, I can get those as well. I'm going to go celebrate with my Dad.*

HCA FL BAYONET POINT HOSP      Name: [REDACTED], JOHN [REDACTED]  
HCA FL BAYONET POINT HOSP      Phys: [REDACTED] MD  
14000 FIVAY RD                      DOB: 09/02/1959      Age: 65      Sex: M  
HUDSON FL. 34667                    Acct: [REDACTED]      Loc: [REDACTED]  
PHONE #: 727-869-5420              Exam Date: 10/15/2024      Status: DEP CLI  
FAX #: 727-869-5493                Radiology No:  
Unit No: Y000584990

**EXAMS:**

007044447 MR BRAIN W/NO CONTRAST

CLINICAL HISTORY: History of glioblastoma in the right temporal lobe.

PROTOCOL: MRI brain without and with 20 mL Dotarem intravenous contrast.

COMPARISON: Prior brain MRI dated 5/28/2024, 4/26/2024, 4/24/2024, and 3/31/2024. Prior CT head dated 9/4/2024, 9/3/2024, 4/25/2024, 4/23/2024. Prior CTA head/neck 9/3/2024, 4/23/2024.

**FINDINGS:****Brain parenchyma:**

No restricted diffusion suggestive of new acute infarct. Redemonstration of cystic and solid mass throughout the right temporal lobe and extending slightly within the periventricular right parietal lobe to abut the occipital horn and temporal horns of the right lateral ventricle. Associated edema throughout the right temporal lobe and parietal lobe is more extensive along the posterior aspect (series 6, image 14-21) to involve the U fibers. Extension along the splenium is slightly decreased since prior exam. Minimal increase along the thalamus. Associated restricted diffusion involving the right temporal lobe mass is slightly less conspicuous in the peripheral enhancing components when compared to prior exam. Previously seen faint increased diffusion signal in the ependymal regions and along the genu no longer appreciated. When evaluating enhancement on spin-echo imaging, favor slight decrease in thickness of the peripheral enhancement in the inferior component of the mass when compared to prior exam (for example series 10, image 11 when compared to prior exam series 11, image 13/series 10, image 10 when compared to prior exam series 11, image 12). Although difficult to measure size of the mass given distribution, favor slight decrease in size of the central

appears decreased superiorly when compared to prior exam. Difficult to evaluate the anterior right temporal horn versus cystic component of the mass which appears increased (series 5, image 13 when compared to series 5, image 15). Inferior mass effect on the third ventricle is improved. Leftward midline shift is not appreciated at the level of the septum pellucidum (previously measured 4 mm). Minimal leftward midline shift at the level of the third ventricle is improved. There is decrease in parenchymal enhancement of the lateral ventricles when compared to prior exam with persistent linear enhancement involving the frontal horns. New additional enhancement is not appreciated. The previously seen edema in the mesial temporal lobe is slightly improved. Faint increased FLAIR signal along the genu of the

PAGE 1

Signed Report

(CONTINUED)

HCA FL BAYONET POINT HOSP  
HCA FL BAYONET POINT HOSP  
14000 FIVAY RD  
HUDSON FL. 34667  
PHONE #: 727-869-5420  
FAX #: 727-869-5493

Name: [REDACTED], JOHN [REDACTED]  
Phys: [REDACTED] MD  
DOB: 09/02/1959 Age: 65 Sex: M  
Acct: [REDACTED] Oc: [REDACTED]  
Exam Date: 10/15/2024 Status: DEP CLI  
Radiology No:  
Unit No: Y000584990

## EXAMS:

007044447 MR BRAIN W/WO CONTRAST

periventricular white matter of the frontal lobes is unchanged. T2/FLAIR hyperintensity in the posterior periventricular white matter of the left occipital lobe is slightly more conspicuous from prior exam. Foci of susceptibility associated with the right temporal lobe mass or slightly decreased from prior exam. No new abnormal susceptibility. Ventricles/extra-axial spaces: Mass effect on the temporal horn of the right lateral ventricle appears slightly improved anteriorly, however the anteriormost component is questionably slightly dilated when compared to prior exam (series 8, image 17). The left lateral ventricle and third ventricle appear

*Note:*

Although the **fenbendazole** and mebendazole are very similar in effectiveness at higher doses, Mebendazole has superior brain cancer cell killing at lower doses compared to **Fenbendazole**. So for Glioblastoma, it's Mebendazole if you can get it. Otherwise, you can't go wrong with **Fenbendazole**. It's still almost as good. ([source](#))

Related: [A Glioblastoma Survivor Story | Dr Justus Hope](#)

## 4. Bile Duct Cancer (Cholangiocarcinoma)

Dr William Makis [shared on X/Twitter](#) (December 2024 update):

IVERMECTIN and FENBENDAZOLE Testimonial - 53 year old Stage 4 Cholangiocarcinoma Cancer patient with 15cm tumor declared "Cancer Free" after reaching out to me 14 months ago!!

This is a very special story.

53 year old Canadian Cancer patient diagnosed with Stage 4 Cholangiocarcinoma, metastatic to liver in March 2023. Multiple lesions, largest 15cm.

Patient had chemo and reached out to me in October 2023

"I was taken off the bag of immunotherapy because the tumour didn't shrink"

"Second oncologist...was worse than the oncologist I have now...told me my supposed mortality chart and to watch for "the end" because I'd be lucky to make it to summer (2024)"

"I'm terrified...I'm losing hope"

I replied on Nov.3, 2023:

"Don't lose hope..

Ivermectin is 1mg/kg/ or 2mg/kg daily  
Fenbendazole is typically 444mg daily  
Melatonin is 100mg-300mg daily" (see note below)

Life went on...then I get an email in July 2024:

"I'm still here thanks to you :)"

In November 2023, she had started **Fenbendazole** 444mg (Panacur) and Melatonin 100mg

In August 2024 we added 150mg of Ivermectin or 2.5m/kg/day, and CBD-THC Oil.

You heard that right. Ivermectin 2.5mg/kg/day.

And then...

December 12, 2024: "Cancer Free".

*Note: "Melatonin induces apoptosis in cholangiocarcinoma cell lines by activating the reactive oxygen species-mediated mitochondrial pathway" ([source](#))*

  Fri, Jul 19 at 10:17 a.m. ☆

**From:**   
**To:** William Makis


Hi there,



I was wondering where you will be seeing patients?



I emailed over a year ago. ([I'm still here thanks you](#)) :-)


Would love an appointment with you because my oncologist is still very robotic and just keeps pumping with chemo with no end in sight.


Let me know.  
Thanks in advance  
  
Direct Line:   
Sent from my iPhone


 **Update** Yahoo/04 - TES... ☆


  Thu, Dec 12 at 2:27 p.m. ☆

**From:**   
**To:**   
**Cc:** William Makis

Hi Dr. Makis,  
We know your extremely busy as we follow you in the media with your platform reaching new levels.  
Just wanted to share the news with you that [my wife is cancer free!](#)  
Thank-you for your guidance we are forever grateful.  
What are your thoughts on the protocol we have been following.  
Daily  
1 tablespoon Ivermectin  
222 Morning Fenbendazole  
222 Night Fenbendazole  
\*Sundays no Fenbendazole  
Should we continue with the same recommended? Should we scale back on either of the products?  
What are your thoughts on the duration of taking these products.  
Thanks,  


On Wed, Dec 4, 2024 at 6:37 PM  > wrote:

Hi Dr. Makis,  
Great news to share with you!  
Can we schedule a quick call?  


 **William Makis**  
From: makisw79@yahoo.com  
To: [Redacted] Wed, Nov 1, 2023 at 5:11 p.m. ☆

Hi [Redacted]

I would consider High dose Ivermectin, Fenbendazole and Melatonin protocols, since this is an aggressive cancer at a Stage 4.


[Could still be curable, however.](#)

William

 [Redacted]  
From: [Redacted]  
To: William Makis Wed, Nov 1, 2023 at 5:40 p.m. ☆

Thank you very much for your reply. This is all new to me. I'm terrified .  
Can you comment on the dosage on each of the outline below and duration?  
Do I cycle on or off?  
Thanks in advance  
[Redacted]  
Direct Line: [Redacted]  
You can also call me. The stress over this is unbelievable. I'm losing hope.

Sent from my iPhone

 **William Makis**  
From: makisw79@yahoo.com  
To: [Redacted] Fri, Nov 3, 2023 at 4:31 p.m. ☆

Don't lose hope,

I have articles on Ivermectin, Fenbendazole and Melatonin on my substack.


The Ivermectin is 1mg/kg or 2mg/kg daily

Fenbendazole is typically 444mg daily

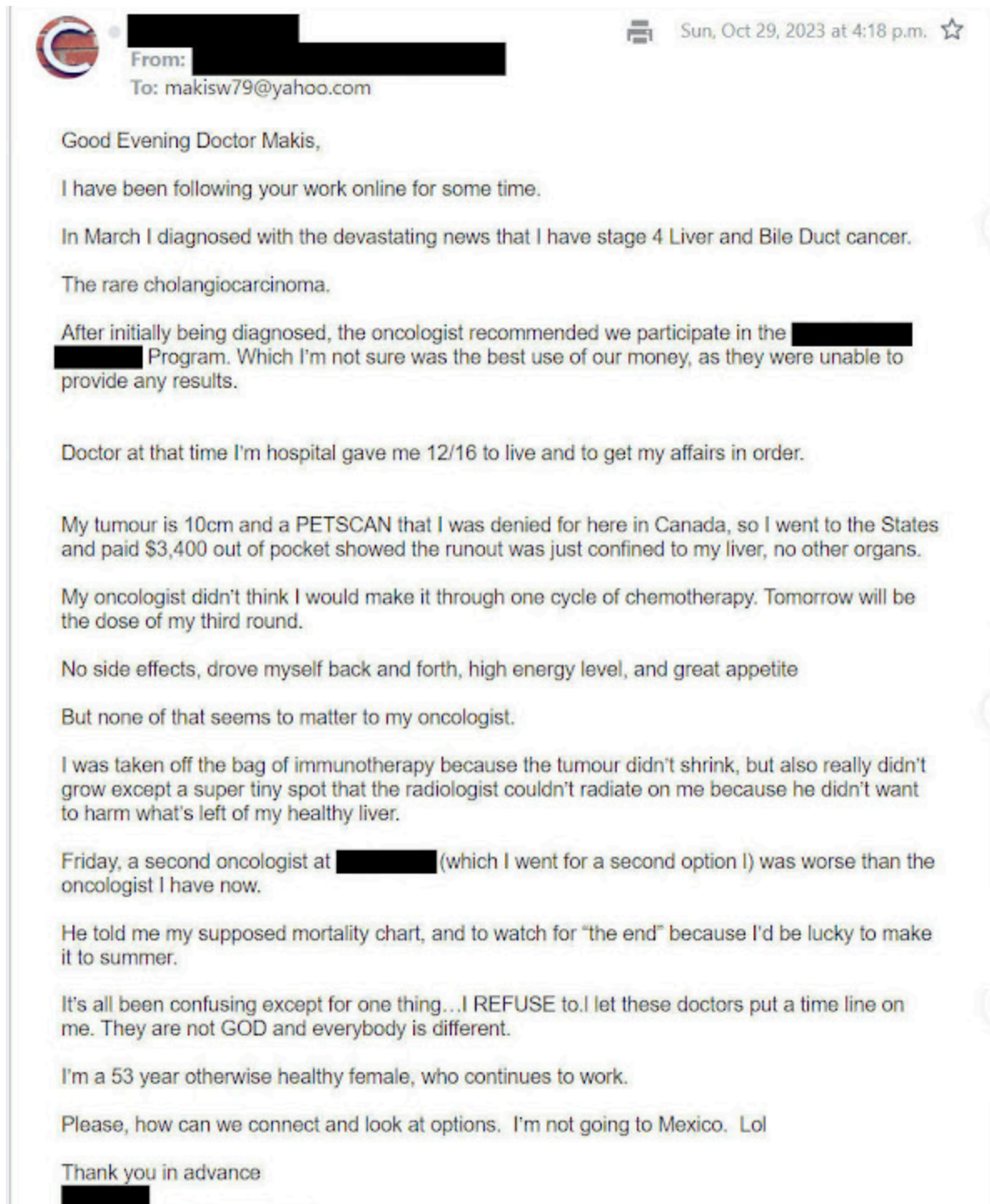
Melatonin is anywhere from 100mg-300mg daily

These are all high dose protocols that people are using for Stage 4 cancers. I can't give you medical advice or recommend specific protocols but these are the doses some people are using

William

 [Redacted]  
From: [Redacted]  
To: William Makis Fri, Nov 3, 2023 at 5:09 p.m. ☆

You have NO IDEA how eternally grateful I am for your response.



## 5. Bladder Cancer Success Stories (5 cases)

### Case 5

Dr William Makis [shared on X/Twitter](#) (Feb 2025):

*"Dr.Makis...I'm writing to inform you about my latest bladder biopsy which was negative. Since 2014, every pathology returned was positive for low-grade papillary urothelial tumors, until now"*

*"I started taking Ivermectin 1mg per kilo. Then somehow I was able to get in touch with you to ask if I should do anything else. You mentioned 444mg of Fenbendazole".*

"Cancer Free for the first time since 2014"

My Take...

"I believe this is my first bladder cancer testimonial. Can you imagine helping someone become "cancer free" for the first time in 10 years?"

Recent research backs the use of Ivermectin + Fenbendazole in bladder cancer:

2024 - Fan et al - Ivermectin Inhibits Bladder Cancer Cell Growth and Induces Oxidative Stress and DNA Damage.

*"Our study showed that in vitro and in vivo, Ivermectin inhibited the growth of bladder cancer cells. In addition, Ivermectin could induce apoptosis, ROS production, DNA damage, and activate ATM/P53 pathway-related proteins in bladder cancer cells. Conclusion: According to these findings, Ivermectin may be a potential therapeutic candidate against bladder cancer due to its significant anti-cancer effect."*

2022 Tung et al - Ivermectin induces cell cycle arrest and caspase-dependent apoptosis in human urothelial carcinoma cells

*"Ivermectin inhibited growth, regulated the cell cycle, and induced apoptosis in human UC cells. It also induced the activation of both extrinsic and intrinsic caspase-dependent apoptotic pathways. Further investigation revealed that ivermectin induced apoptosis in UC cells is mediated via c-Jun N-terminal kinase signaling. Herein, we demonstrated that Ivermectin can be used as a new therapeutic agent for treating UC cells."*

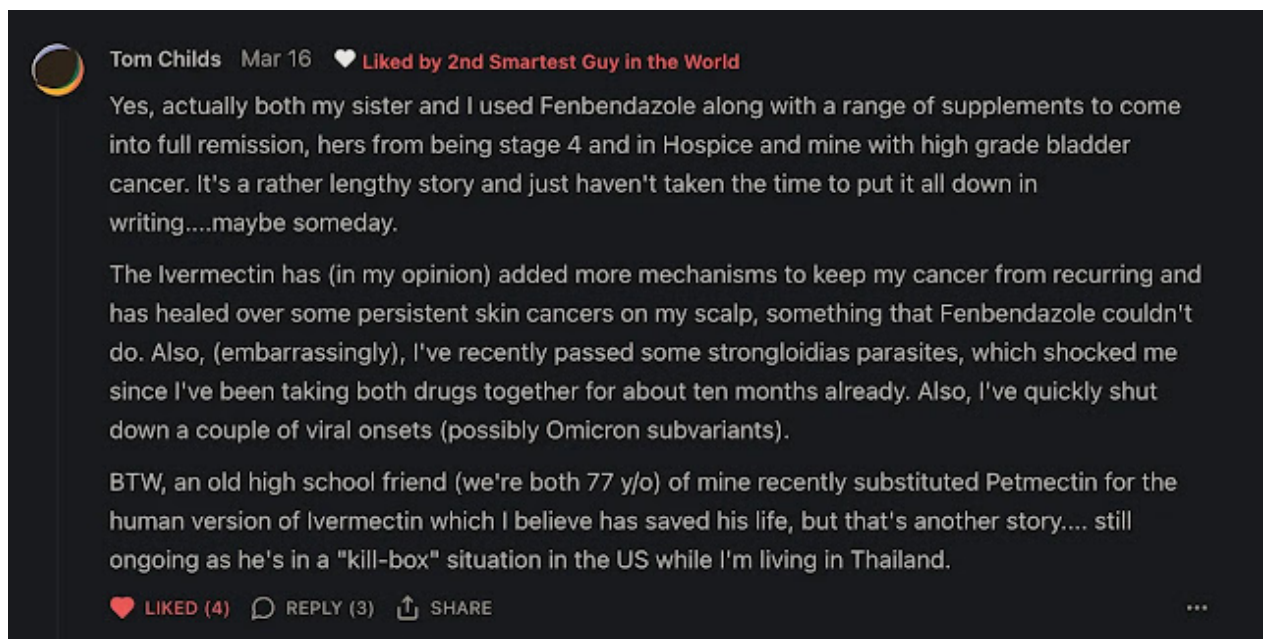
2021 Chiang et al - Fenbendazole Enhancing Anti-Tumor Effect: A Case Series

"A 63-year-old Caucasian female presented with increasing lower urinary tract symptoms and

was no evidence of metastatic disease, consistent with clinical T4 tumor. Transurethral Resection of Bladder Tumor (TURBT) demonstrated a large necrotic mass with pathology confirming urothelial carcinoma with 85% squamous and 2% sarcomatoid histology. She was treated with Accelerated Methotrexate, Vinblastine, Doxorubicin, and Cisplatin (AMVAC) for 6 cycles over the course of 4 months along with concurrent **Fenbendazole** (FBZ) 1 gram three times weekly. Follow-up CT revealed no evidence of disease with minimal residual thickening in the right inferior bladder wall. She declined to proceed with cystectomy and remains on surveillance with no evidence of progression.”

- Ivermectin 1mg/kg/day.
- **Fenbendazole** 444mg/day

#### Case 4



**Tom Childs** Mar 16 ❤️ Liked by **2nd Smartest Guy in the World**

Yes, actually both my sister and I used Fenbendazole along with a range of supplements to come into full remission, hers from being stage 4 and in Hospice and mine with high grade bladder cancer. It's a rather lengthy story and just haven't taken the time to put it all down in writing....maybe someday.

The Ivermectin has (in my opinion) added more mechanisms to keep my cancer from recurring and has healed over some persistent skin cancers on my scalp, something that Fenbendazole couldn't do. Also, (embarrassingly), I've recently passed some strongloidias parasites, which shocked me since I've been taking both drugs together for about ten months already. Also, I've quickly shut down a couple of viral onsets (possibly Omicron subvariants).

BTW, an old high school friend (we're both 77 y/o) of mine recently substituted Petmectin for the human version of Ivermectin which I believe has saved his life, but that's another story.... still ongoing as he's in a "kill-box" situation in the US while I'm living in Thailand.

❤️ LIKED (4) 💬 REPLY (3) ↗️ SHARE ...

source: <https://substack.com/home/post/p-155091883>

#### Case 3

Shared by **2nd Smartest Guy in the World** (2023):

Wonderful!

Yes, I take three Ivermectin and one Doxycycline when I get up in the morning with a large, 16 oz glass of water. I wait an hour and have some light food(organic eggs and avocado slices,

At around 5 p.m. I take three Fenbendazole with a light meal with little carb and higher fat/protein.

I started protocol on 11/11/23.

I had surgery on the 22nd of November for the removal of three cancerous tumors from my bladder(my third surgery, and will have an MRI in two weeks to see if muscle invasive as was before.)

As a result of my 11/11 initiation protocol I noticed an area the size of a dime below my left clavicle disappear ( a skin lesion that I had had for 2-3 years that was raised and would be prone to slight bleeding when rubbed too hard with a towel) to now virtually nothing.

I know this protocol was the reason for this healing. Thrilled! I feel this regime is doing the same to any cancer I may have left in my bladder area. I'll keep you posted.

I am so grateful to you.

Thank YOU!!!!!!

Best, K.

(Please note that K. is using a modified ketogenic diet to starve the cancer of sugars and carbohydrates, which we know is what feeds cancers. An important article on this subject is forthcoming, along with a new product that not only serves as a sugar replacement, but, also, helps eradicate both cancers and diabetes.)

## **Case 2: February, 2023 (updated)**

Condition: Plazamacytoiod Bladder Cancer

July 2022:

I was told from the pathologist report that I had Plazamacytoiod cancer after they removed two tumors from my bladder. I was informed that this type of cancer is very rare and is highly aggressive and that it doesn't respond to chemo or radiation and that I was a candidate for bladder removal. I asked how long I had to live and they said they couldn't tell me for sure maybe a year maybe 6 months they didn't know how it was going to react. The it was between

I walked out with my death sentence in my hand on the papers they gave me of the report an letter from the Dr. It was a difficult time, but I have been in recovery from alcoholism an drug addict for 10 years as of the 2nd of April 2022, this was on April 22nd 2022. I refused to accept it I thought that there must be something I could do I prayed to God for direction!

I thought about contacting MD Anderson and donate my body to them for trials they wanted money up front!! I post my condition on face book so my friends would know, I begin to get calls and text about people using Fenbenzadole found in Dog Dewormer so I googled it and found it.

I started taking Fenben last part of April 2022, and it is July 19th now an I'm still taking it. I quit my job came back to Oklahoma and contact OU Cancer hospital. I went July 15th an had CT's an scans done to see what the cancer was doing an how it had spread. The Dr. came in and said he couldn't see any cancer anywhere in my body that had spread and that he couldn't see any cancer anywhere else or any Tumors or cancer in my Bladder!!!

I take Fenbenzadole every day I have changed my diet I eat only fish an chicken no meat with blood in it, I drink hot lemon juice once a day I eat all kinds of berries an fruits, take vitamins an I believe that that God has healed me through this medicine an I pray that you don't give up any do what you must if it healed me then maybe it can heal you too.

Update – February 2023:

Yesterday I received my PET scan report. No signs of any METASTATIC DISEASE ANYWHERE! MRI of my brain was NORMAL, NO SIGNS OF CANCER OR TUMORS ANYWHERE !! These factors prove that FENBENZADOLE AND TURMERIC CURCUMIN AND CHANGES IN MY DIET HAVE KILLED THIS RARE AND HIGHLY AGGRESSIVE CANCER WITH KNOW KNOWN CURE ALONG WITH FAITH IN A GOD THAN CAN PERFORM MIRACLES AND STUN THE MEDICAL PEOPLE WHO ARE IN DENIAL ABOUT THIS DRUG!! NOW must continue to follow this path and make the changes to keep cancer free and use Fenbenzadole as I must. Thank you and never give up !!!

Listen here for an interview with Earnest: [Earnest Best was Given the Death Sentence and He Didn't Take It.](#)

**Case 1: December, 2021**

on the inside of my uterus. The tumor was removed as soon as possible with several immunotherapy BCG treatments that followed (delivers immunotherapy drugs directly to your bladder through a catheter).

## 6. Cervical Cancer Success Stories

### Case 1: October 2024 and November 2024 Update

**November 2024** - Case study from Dr William Makis ([X/Twitter](#)):

IVERMECTIN & FENBENDAZOLE Testimonial - 50s year old Stage 4 Cervical Cancer patient - CA125 drops 46% in 2 months on high dose protocol!

50s year old Stage 4 Cervical Cancer metastatic to liver patient (USA)

We started a Protocol early Sep.2024: Ivermectin 2mg/kg/day (split over 2 doses)

Fenbendazole 2000mg/day (split over 2 doses) Continue ongoing Tivdak (Tisotumab vedotin) (there was no improvement in CA125 on it so far)

(we switched Fenbendazole brands after a few weeks, when CA125 hit 99.1) Results: 46% drop in CA125 in 1.5 months !

The picture of the CA125 trend is worth a thousand words!

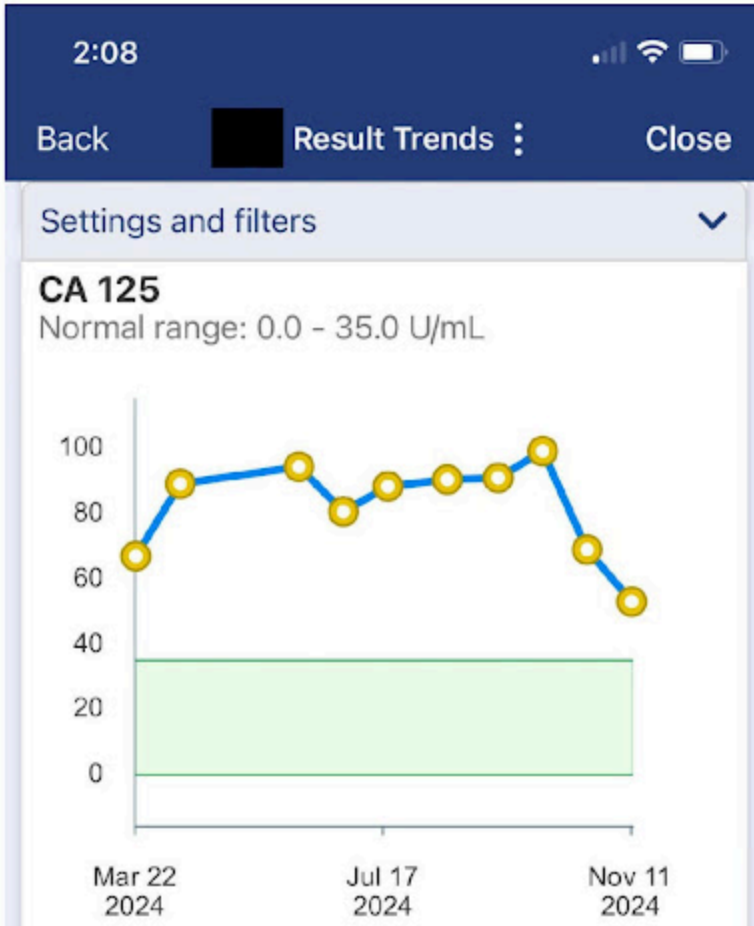


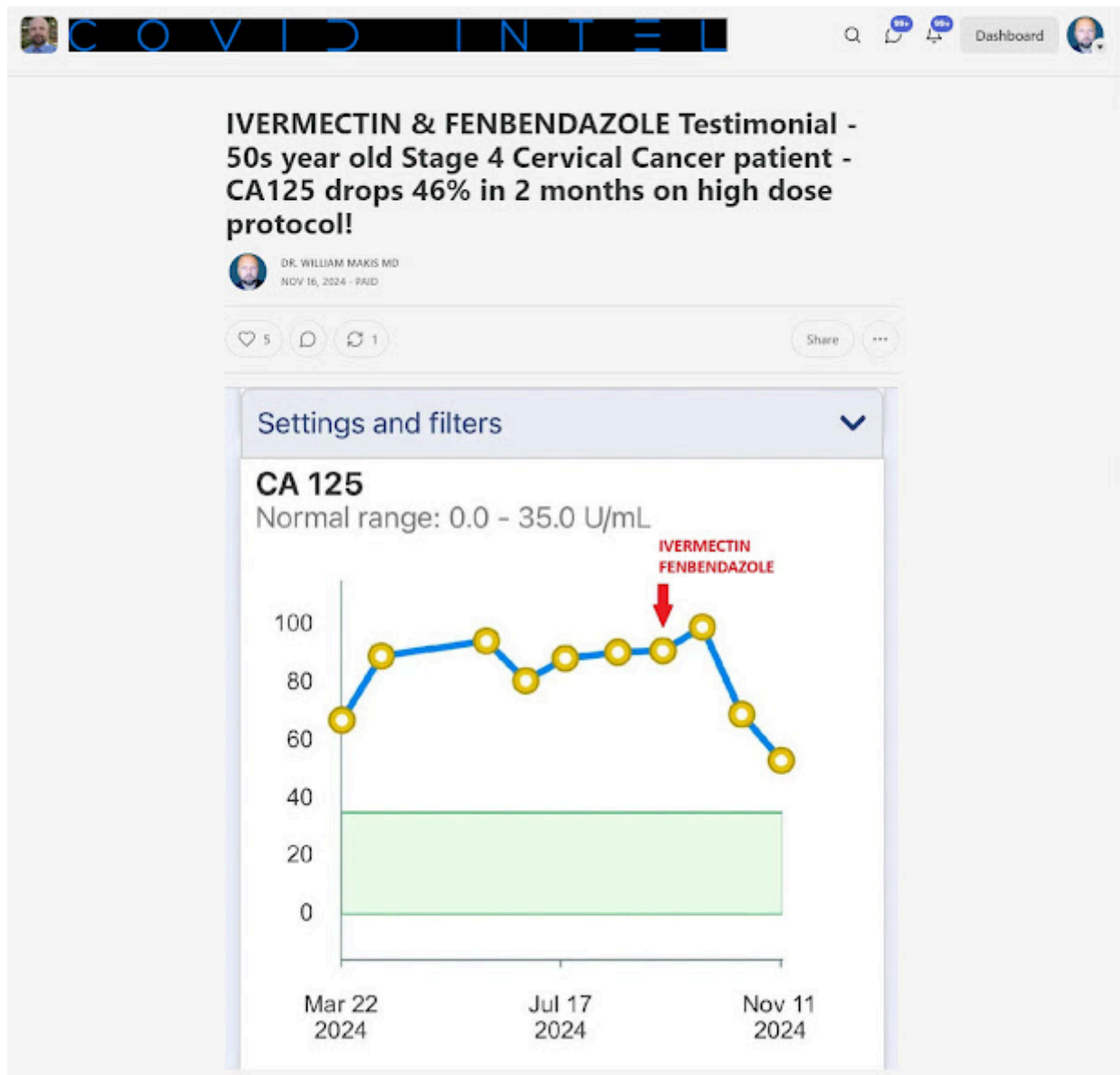From: [Redacted] .com  
To: William Makis

Mon, Nov 11 at 12:33 p.m.

Hi Dr. Makis.

[Redacted] 9th tivdak treatment was today. We just received her CA125 and it is down another 16 points. So that makes it 46 points since you helped us adjust her ivermectin and fenben.





**October 2024** - Case study from Dr William Makis (X/Twitter):

*IVERMECTIN & FENBENDAZOLE TESTIMONIAL - Stage 4 Cervical Cancer patient sees first dramatic drop in blood cancer markers after a few weeks of adjusting Ivermectin & Fenbendazole doses!*

*We started a High Dose Ivermectin/Fenbendazole Protocol beginning of September and after 4 weeks the CA125 value hadn't changed, it had gone from 91U/mL to 99.2U/mL which I considered stable but a little bit stubborn.*

*We were a bit slow getting the Ivermectin up, so I increased it by 30% increments to +100%.*

*In just 3 weeks! You have to be able to adapt and fine-tune. Ivermectin really does work at higher doses. But sometimes it's not easy to get there. And for **Fenbendazole** you CANNOT be married to a brand. Mix things up. If you feel a brand is not working, add a completely different brand! DON'T BE AFRAID TO CHANGE BRANDS! That's the lesson here. Be flexible.*

30 point drop!!!!!!!!!!!!!!!!!!!!

Yahoo/03 - TES... ☆

From: [REDACTED]  
To: William Makis

Mon., Oct. 21 at 12:39 p.m. ☆

Dear Dr Makis,

I can barely contain myself as I type this email.

My sister's CA125 dropped 30 points in 3 weeks after we implemented the increase in ivermectin and switched from happy healing to Sanare labs fenbendazole:

Jun 7, 2024 - Sep 9, 2024 (Table 5 of 6)					
Component	Jun 7, 2024	Jun 28, 2024	Jul 19, 2024	Aug 16, 2024	Sep 9, 2024
CA 125 Normal Range: 0.0 - 35.0 U/mL	94.4 U/mL	80.7 U/mL	88.4 U/mL	90.5 U/mL	91.0 U/mL

Sep 30, 2024 - Oct 21, 2024 (Table 6 of 6)		
Component	Sep 30, 2024	Oct 21, 2024
CA 125 Normal Range: 0.0 - 35.0 U/mL	99.2 U/mL	69.1 U/mL

She just finished her 8th Tivdak treatment today — while I believe the Tivdak is contributing to the success (perhaps), I actually believe it's the increase in ivermectin that is having the greatest impact on her numbers. Especially since we reduced her dose of Tivdak after session 5 b/c of the harsh side effects. And the only thing to change in the past 3 weeks is what we did based on your recommendation

She is adding a second source of fenben to the Sanare labs formula (per your recommendation) — FenBen Pure Powder from Happy Healing (she had been using the happy healing tablets which I felt were not being absorbed). So she will do Sanare in the morning and Happy Healing at night. And we will continue on the higher iver.

Dr. Makis, I know you are going through a lot right now, but please know you are making a difference in people's lives. Saying thank you isn't sufficient...I owe you so much.

I will update you in 3 weeks after her next treatment as we continue on this journey...also she has a big scan in November.

Thank you again, so much.  
[REDACTED]

<https://makismd.substack.com/p/ivermectin-testimonial-stage-4-cervical>

**COVID INTEL** 🔍 📧 📧 Dashboard 👤

## IVERMECTIN TESTIMONIAL - Stage 4 Cervical Cancer patient sees first dramatic drop in blood cancer markers after a few weeks of adjusting Ivermectin & Fenbendazole doses!

 DR. WILLIAM MAKIS MD  
OCT 27, 2024 - PAID

👍 18 💬 🔄 Share ⋮

**FENBENDAZOLE**



**IVERMECTIN**



## 7. Colorectal Cancer and Fenbendazole (11 cases)

Case 11: December 2024 - 84 yr old Colon Cancer patient

Dr William Makis shared on [X/Twitter](#):

"IVERMECTIN and FENBENDAZOLE Testimonial - 84 year old Colon Cancer patient from Argentina "essentially on his deathbed" sees significant improvement with low doses!"

"I am from Argentina...My father is very ill; he is bedridden and weak at 84 years old, and he

"Refuses to go to the hospital because he is so weak and is essentially on his deathbed."

"I gave him 500mg of Fenbendazole once, along with a very low dose of 12mg of Ivermectin, and he showed significant improvement"

"Please continue your important work; you are making a difference"

"I am sharing this because it is a reminder that even in the most dire situations, you can have a significant impact on someone's quality of life! Don't underestimate the impact that Ivermectin and Fenbendazole can have, even in the short term."

**From:** [REDACTED]  
**Subject:** [REDACTED]  
**Date:** December 11, 2024 at [REDACTED]  
**To:** [REDACTED] >

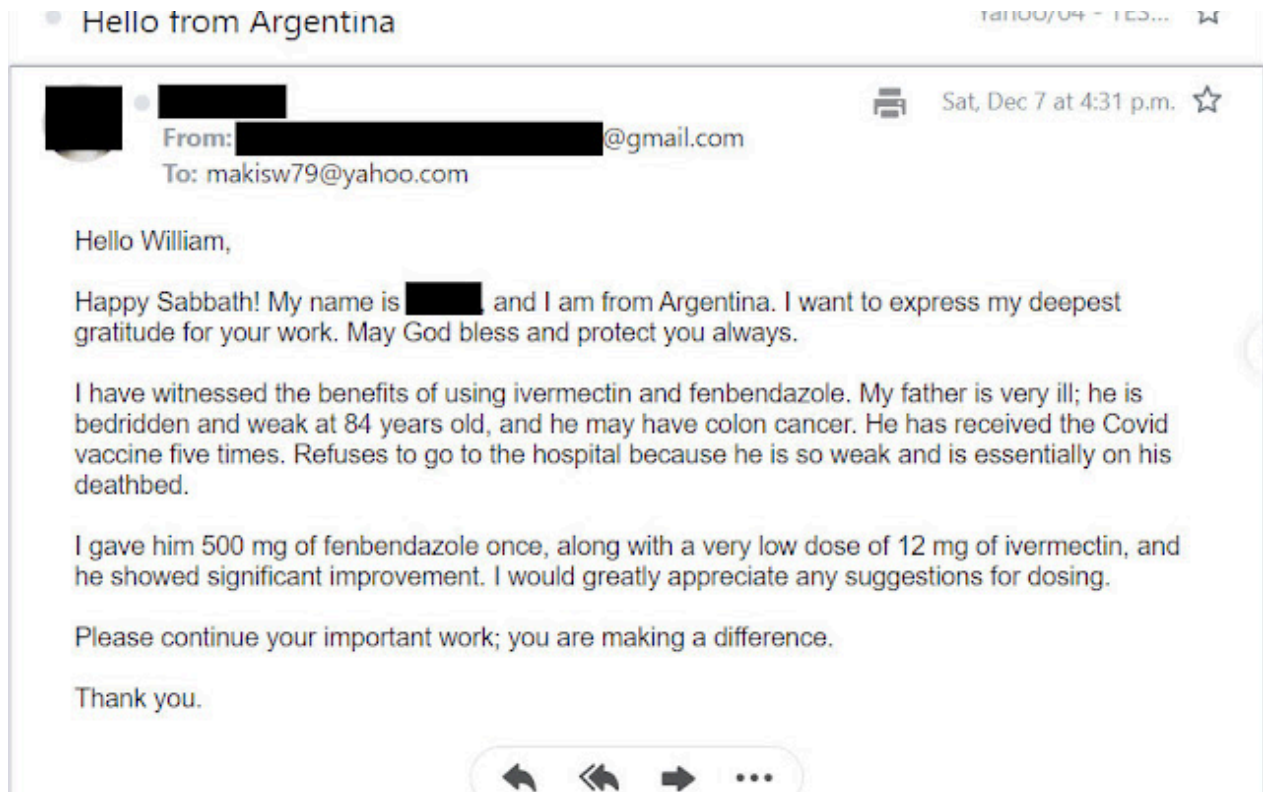Hi [REDACTED],

We appreciate your good intentions with getting Dad alternative care. However, we discussed this and the two medications with his team and they were highly concerned about the side effects. One of them is actually supposed to be for animals (not humans) and the other they feel would likely lead to death as the side effects would be too harsh for him.

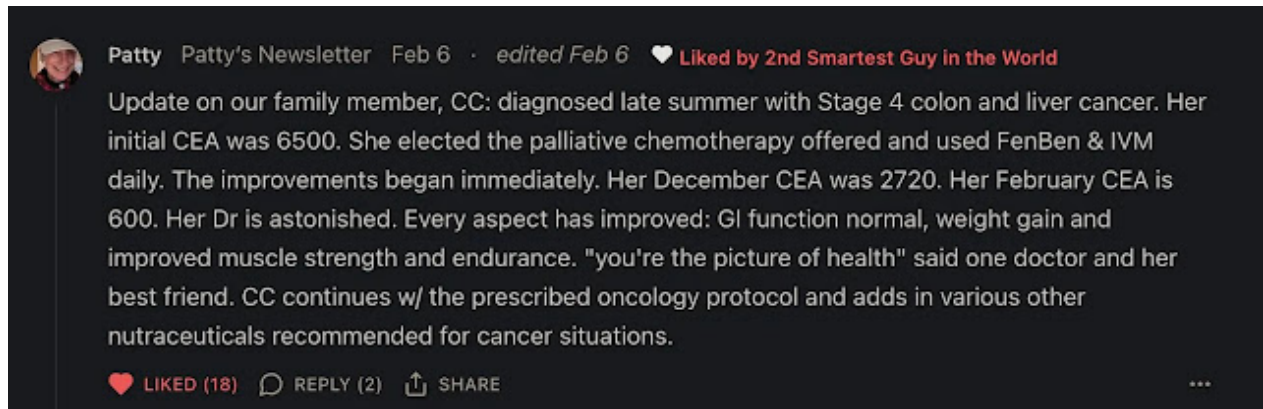
His consent form says to discuss with your doctor first so we did and do not feel like this is a good plan of action.

Again, we appreciate your concern and thoughtfulness but this isn't a course we feel is in dad's best interest.

[REDACTED]  
Sent from my iPhone



Case 10:



source: <https://substack.com/home/post/p-155091883>

Case 9

strongly pressured to go the painful chemo/radiation route but fortunately he declined. He started on a daily program of 1 tsp baking soda in water, 2 cups of soursop tea and ivermectin and Fenbendazole. He had a second opinion scheduled some months later and they found his tumor had shrunk to 3 cm. There was no curiosity about why it had shrunk and they wanted to do the same protocol as the first oncologists.

♥ LIKED (25) ◻ REPLY (1) ↗ SHARE ...

source: <https://substack.com/home/post/p-155091883>

### Case 8: October 2024 - Stage 4 Colorectal Cancer with liver metastases


Another success case study from Dr William Makis (X/Twitter):

*IVERMECTIN & FENBENDAZOLE Testimonial in Stage 4 Colorectal Cancer with liver metastases - Patient in his 60s - dropping CEA and chemo side effects disappear completely!*

*Sometimes a patient is taking chemotherapy when I get consulted for assistance. So when I suggest a high dose Ivermectin and Fenbendazole Protocol, it comes with two confident predictions:*

- 1. You'll have a better outcome than chemo alone*
- 2. You'll have less chemo side effects*

*Sometimes cancer patients give me a look. It's that "are you sure?" Look. And I just smile. Because I get to see testimonials like this. And I absolutely love seeing it! And yes, within a month we had the CEA levels dropping like a rock too...*

 **William Makis** Thu., Oct. 3 at 10:09 a.m. ☆  
From: makisw79@yahoo.com  
To: [REDACTED]

This is excellent!

William

On Thursday, October 3, 2024, 09:08:21 a.m. MDT, [REDACTED] wrote:

Morning William,

Had to share updated labs from this morning.

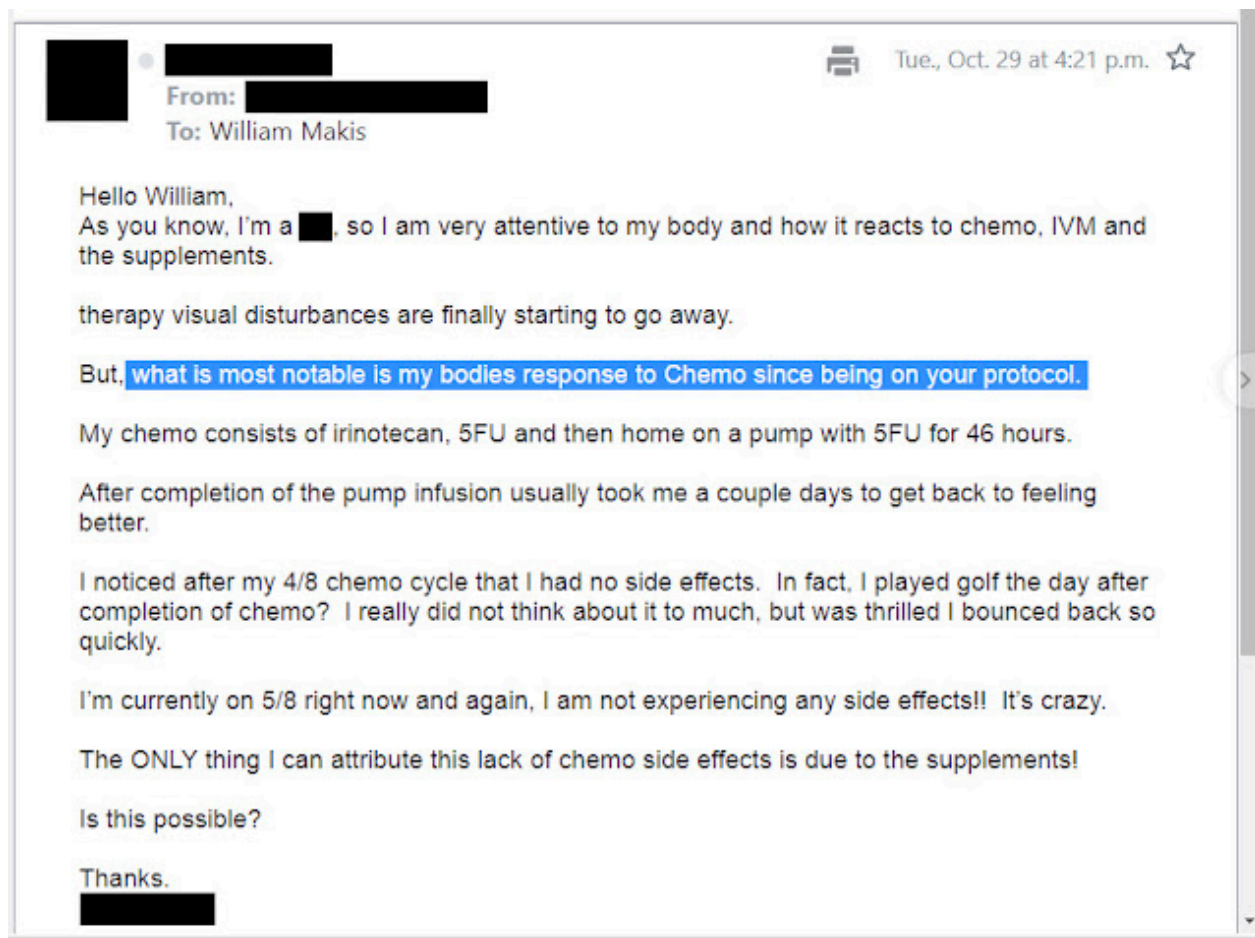
Bili was 2.4. Today: 1.3  
**CEA was 13.7. Today: 7.5**

Taking all protocol drugs.

Thanks for your input and support.

[REDACTED]

[REDACTED]



**IVERMECTIN & FENBENDAZOLE Testimonial in Stage 4 Colorectal Cancer with liver metastases patient in his 60s - dropping CEA and chemo side effects disappear completely!**

DR. WILLIAM MAKIS MD  
DCT 30, 2024 - PAID

7 likes, 0 comments, 0 shares

**FENBENDAZOLE**

**IVERMECTIN**

ONE MONTH IN....

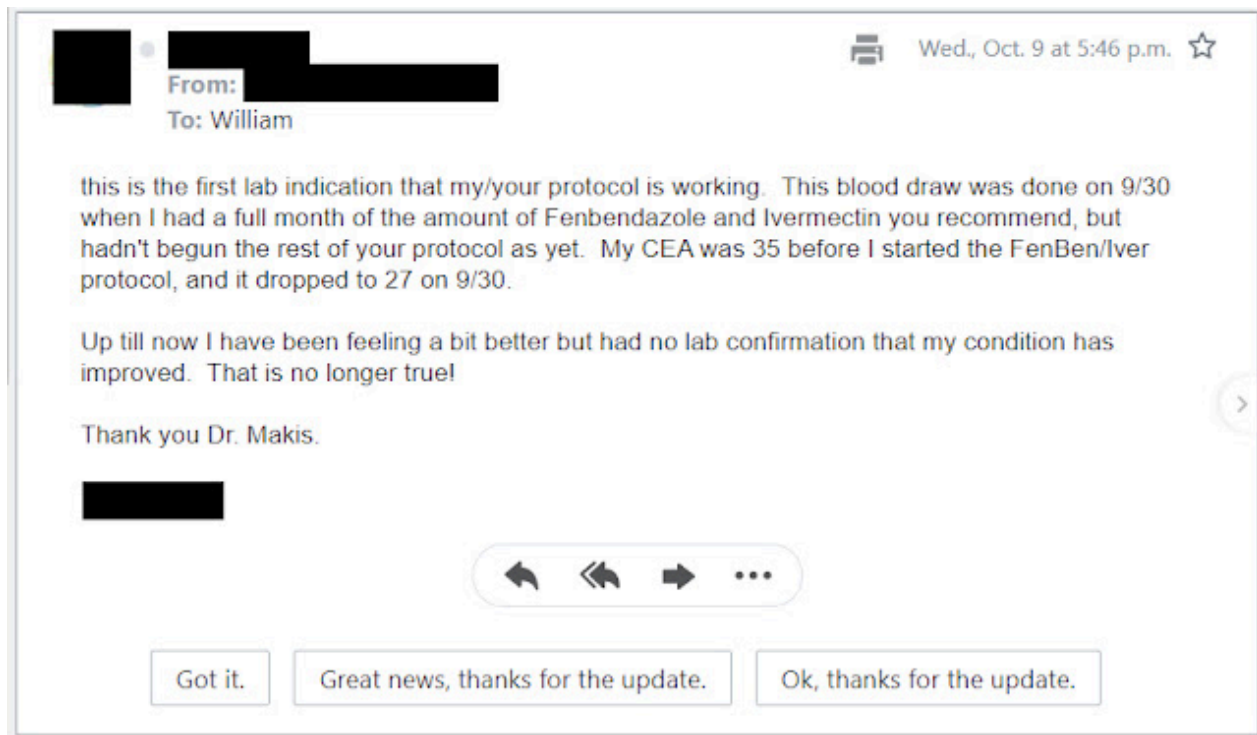
### Case 7: August 2024

William David Krawsczyn shared on a [Facebook Group](#):

I was diagnosed 9 years ago with stage 4 colon cancer! Colon, liver, lymph nodes! 44 chemotherapy treatments, 6 surgeries, 3 recurrences of cancer! I have taken **fenbendazole** and ivermectin off and on during **last 9 years!** Now have a recurrence of cancer and need to know dosage (ml.'s orally) of each and frequency! I have oral goat dewormer (**fenbendazole**) and injectable cattle dewormer (ivermectin)! Need to know how much of each to take orally and frequency??

### Case 6: October 2024

Another success case study from Dr William Makis ([X/Twitter](#))



### Case 1: February, 2023

Praise report: His colonoscopy ( her husband) is done and the doctor said not even 1 polyp! He said he won't need to see him for 3 years. we feel beyond blessed and will continue the low dose maintenance fenben protocol. I just want to express how grateful I am to have found this group ( and all the amazing support that comes along with it! You are all amazing and in my daily prayers!

### Case 2: January, 2023

Success story! My husband had stage IV colon cancer detected from first colonoscopy at age 50. He is a very disciplined ex- Marine and once he wrapped his head around the fact that he had cancer and his health was in his control he HIT IT as hard as he could from all angles and it has thus far worked!

He is NED 8 months after initial diagnosis. I have snippets of what he did to get to NED from stage IV colon cancer. We continue to change the protocols as we learn from everyone, as well as other sources. Best wishes to everyone!

### Case 3: August, 2022

I was give a bleak 12-18 months with the hope of making it through Christmas 2018. I was offered palliative chemotherapy for end of life pain management, but decided to start taking a number of alternative methods alongside the palliative chemotherapy and continued to take until I finally reached remission.

What I took to get to remission after palliative chemo was all on offer (palliative chemo finished on the 25th March 2019).

Scott Davis protocol –

- 2000 mg cbd oil 4 capsules (18-20 drops) x a day 🌱
- THC oil 4 capsules (18-20 drops) x a day (feco 1:1 mct) 65-75% thc. 🌱 I do this at 08:00-12:00 – 16:00 – 20:00
- Milk thistle twice a day. (2000mg) 💊
- Vitamin d3 twice a day. (4000iu) 💊 – Curcumin twice a day. (4000mg) 💊
- Vitamin c once a day. (1000mg) 💊
- Vitamin b12 once a day 💊
- Cod liver oil. 💊
- Vitamin e once a day 💊
- Berbine. (1000mg) x 2 💊
- B17 apricot seeds. (22 mg) x 4 💊 – Aspirin (1/2) a day 💊
- Cellfood supplement in my water. 💧 – 4.5 gram a day everyday of panacur (999mg fenbendazole) (started on the 22nd May 2019 finished January 2020. ) 🐶

I reduced my sugar and dairy intake as much as possible and tried to eat a healthy plant based diet with the occasional bit of chicken or turkey. I also drink 5 cups of green tea a day and added berbine (1000mg x 2 a day) and added turkey tail mushrooms and lions mane mushrooms.

After remaining stable and contained from January 2019 for over 12 months I finally got the PET scan results I'd dreamed of. "no active cancer". (February 2020.) CT scan in August 2020 continued to show improvement and only shows scare tissue where the inoperable Tumour once was.



#### Case 4: August, 2022

Hi everybody. I just wanted to share my story with you. On June 11, 2021 I was diagnosed with stage 4 colon cancer with multiple Mets to the liver ... I am labeled, "incurable ". When I had a colonoscopy, they couldn't get the camera past a certain point because the cancer was so thick. 2 months later I had a couple of blockages and had a colon resection done. At this point the cancer took me from 210 pounds down to 165 pounds. I was so scared that I was on my way out. I started the Joe Tippens protocol at this time. Fast forward to today, and the cancer is gone from my colon and we are focusing on the liver. My blood test have come back perfect the last 4 blood test. My oncologist is so excited that he order a CT scan in a couple of weeks. The first photo is when I felt I was on my way out. It's still hard to see myself like that. The second photo is a couple of weeks old of me camping in the mountains. I really feel that Joe Tippens protocol helped save my life. I'm so thankful for being here and I'm blessed to have each day. Thank you for listening.

#### Case 5: July, 2022

Positive Results!

My wife was diagnosed with stage 4 Colon Cancer on 3/15/22 just 4 months ago. Mets to base of skull, adrenal glands. Before she had terrible pain at the base of her skull and was on Endone and other pain killers. We found out about Joe Tippens story and started **Fenbendazole** immediately at 222mg twice a day and then gathered other supplements. 5 days after Fenben her pain was gone. We watched Joes videos and also came across Jane McLelland's Book "how to starve cancer". From that we enrolled in her online course to gain better insights and from there we got in touch with the Care Oncology Clinic.

My wife has had only 5 chemo sessions and 1 cycle of treatment radiation over 10 days for

Today her Cancer is all but GONE!! in just 4 months. She was given between 6 months and 2 yrs to live and is now basically NED. We would 1st like to thank The Lord Jesus Christ our healing Saviour, Joe for having the guts to try something which and face the ridicule of the public and the medical profession. We would like to thank Jane for her tenacity in overcoming her own battle but much more in researching and publishing the info so that the avg person can understand and beat this insidious disease. Also we are very grateful and would like to thanks the Care Oncology Clinic in UK for their help in refining our protocol for My wife's particular type of cancer.

Also our Surgeon who put in a stoma called today and will now reverse the operation to remove her colostomy bag as the tumour is all but gone.

We are aware that it's possible the Cancer may return but it's now like treating a chronic disease such as diabetes rather than a death sentence. With regular blood tests and scans we can now stay on top of this instead of being a slave to it.

Below is a copy of her results with names and places cut out. If you have been told that Cancer is a death sentence don't believe it as there is hope. You just have to get the right info.

**F18-FDG PET-CT SCAN****Clinical Details**

Metastatic colorectal adenocarcinoma. Assessment of disease.

**Technique**

Patient consultation. PET and non-diagnostic AC AL CT were acquired from skull vertex to knees 60 minutes after I.V administration of 186MBq F-18 FDG. BSL was 4.9mmol/L. Diagnostic contrast enhanced CT HCAP.

**Findings**

Comparison with 15/03/2022.

**Head and Neck**

There is no significant residual abnormal FDG uptake above physiological background in the previously seen intensely FDG avid infiltrative metastatic disease throughout the left occipital condyle, clivus and basiocciput. The left neck lymph nodes have resolved. No intracranial mass. Grey-white matter differentiation and cerebral contrast enhancement is normal.

**Thorax**

The left thoracic inlet lymph node has resolved. The posterior mediastinal and retrocrural lymph nodes have resolved. Lungs are clear. No effusion.

**Abdomen and Pelvis**

The abdominopelvic nodal disease has also resolved, (less than 4 mm in short axis on CT and non-avid). No new lymphadenopathy. The sigmoid the tumour shows residual mild wall thickening on CT and mild FDG uptake, significantly regressed from the previous intense FDG uptake. No evidence of liver metastasis noting several simple cysts which are unchanged. Background diffuse liver steatosis is also noted. There is no omentoperitoneal disease evident. The other abdominal viscera are

1 2

Authored by: Dr Dalveer Singh

satisfactory. No free fluid.

**Musculoskeletal**

Diffuse reactive marrow uptake is noted.

**Impression**

The metastatic nodal and skull base disease shows a complete metabolic response to therapy when compared to 15/03/2022. A near-complete metabolic response to the sigmoid primary tumour, now showing only mild wall thickening on CT and low level uptake. No new metastasis.

Read More about Colorectal Cancer in [Colon Cancer: Types, Risk Factors, Symptoms, Diagnosis, Staging and Treatment](#).

## 8. Esophageal and Stomach (Gastric) Cancers (4 cases)

**Case 4:** 74 year old man with a 28cm GIST Tumor\* (Gastro-Intestinal Stromal Tumor)

Dr. William Makis [shared on X](#) (Twitter) in March 2025:

Ivermectin and **Fenbendazole** Testimonial - 28cm GIST (Gastrointestinal Stromal Tumor) starts shrinking in a patient who had to go off Gleevec due to side effects, 50% drop in tumor activity!

World's first case. This has never been tried before.

We started: Ivermectin 108mg/day and Fenbendazole 1776mg/day.

Results after 1 month:

- 47% decrease in tumor's metabolic activity
- 1.1cm shrinkage of tumor
- resolution of abdominopelvic ascites
- improved appetite
- decreased mass pressure on the stomach

From patient: "We met with our oncologist this afternoon and he was surprised to see the great results because XXX has not been allowed to take Gleevec for 4 weeks and he said typically the cancer activity will increase"

"Well, XXX's PET scan showed a dramatic decrease in activity from SUV 5.78 down to SUV 3! He said normal cells are at 2.5"

*\*Note: A type of sarcoma, a rare type of cancer that can be difficult to diagnose and treat.*

### Case 3: December 2024

Dr William Makis shared on [X/Twitter](#):

IVERMECTIN and FENBENDAZOLE Testimonial - 60s year old California man with Stage 2 Gastric Cancer improves significantly on PET/CT after 2 months! (no chemo, no immunotherapy, no radiation).

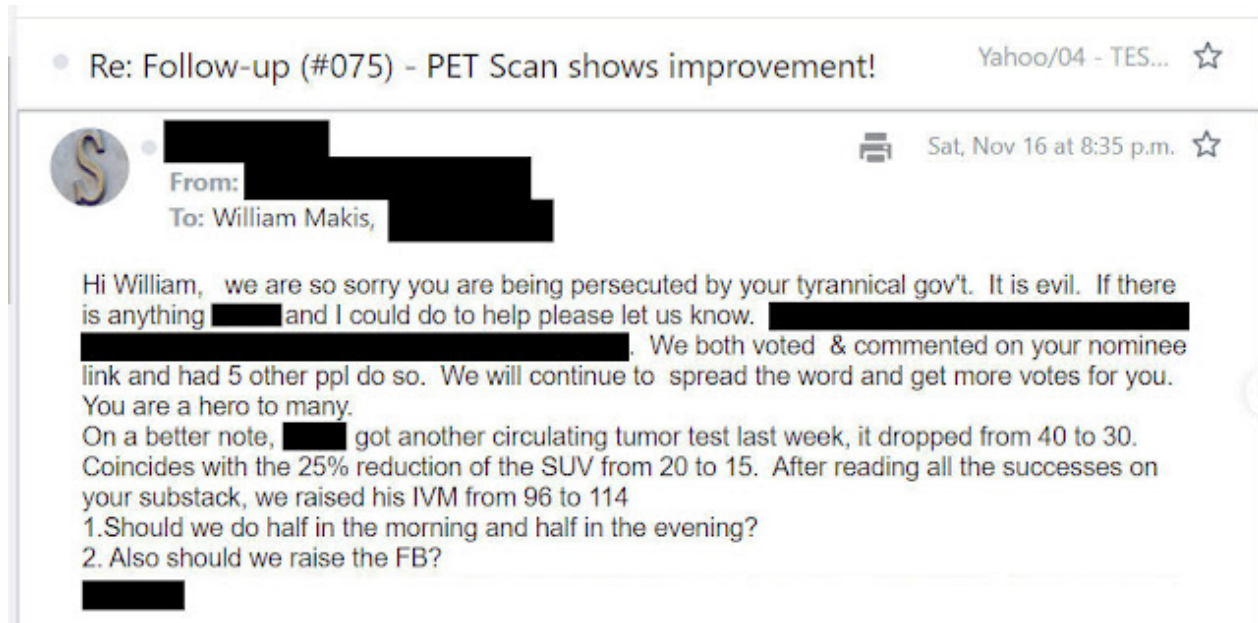
60s year old California man was diagnosed with Stage 2 Gastric (Gastro-Esophageal Junction) Adenocarcinoma on July 31, 2024. Started Ivermectin early August 2024 (36mg bid)

He had a staging PET/CT Scan late Aug.2024 which showed a metastatic lymph node, and he then started 444mg Fenbendazole.

I became involved and suggested higher doses: 96mg Ivermectin and 888mg Fenbendazole

RESULTS: PET/CT Aug.23 compared to PET/CT Oct.24, showed: Primary GE Junction tumor SUV 20.5 decrease to 15.6, similar size

effects of high dose Ivermectin and Fenbendazole on tumors, with metabolic imaging via PET/CT. In this case, we see two tumors with a 25% drop in metabolic activity in 2 months. On a CT scan, the lesions would look stable but metabolic information tells us 25% of the tumor has been killed off. It takes a bit longer for the body to start clearing the dead cancer cells. Once again, this patient had no chemo, no immunotherapy, no radiation, no conventional Oncology treatment of any kind. Only Ivermectin and Fenbendazole, both well tolerated.



On Sat, Oct 26, 2024 at 3:16 PM William Makis <[makisw79@yahoo.com](mailto:makisw79@yahoo.com)> wrote:

PET scan:

GE Junction mass same size, SUV 15.6 down from 20.5  
Peripancreatic LN same size, SUV 15.9 down from 21.1  
No new lesions

Overall, the tumors are showing 25% decrease in metabolism, which means 25% of the tumor has either died or gone inactive compared to last time.

You're on the right track.

William

[REDACTED] wrote:

Hello William

I think I told you we are at the Cancer Center [REDACTED] in [REDACTED]. Dr [REDACTED], medical director, knew of you and fully embraced your protocol.

[REDACTED] is currently on the 96mg IVM and 888mg FB. Starting with lower doses adding the higher doses about 66mg Ivm and 444 FB on Aug 18. We had the DATAR and RGCC tests taken, I have attached the results. We are asking our doctor what test we can take again to see if the tumor has had any change.

Another endo w/ultra sound (1st one aug 6), ct w/contrast (1st one aug 1) or pet scan (1st one aug 23). Which do you think would be most definitive and safe?

We finally received the addendum from the biopsy which I am also attaching.

The center does fractional low dose chemo but after seeing the addendum recommends another dr outside of their clinic that does immunotherapy (since the center doesn't do this) instead of the low dose. Your thoughts? [REDACTED] does not want to do the low dose chemo, we are so leary of its toxic side effects to his whole body. We so value your opinion. Thank you [REDACTED]

PS hope Japan was a success

## Case 2: November 2024

Sam shared on [X/Twitter](#):

*Quick appreciation post for Dr Makis a month ago I wasn't making Xmas now thanks to his high dos ivermectin/ fenbenazol protocols I've put on 6kg this month and feel like I'm back winning the fight against stage 4 gastric cancer.*

## Case 1: September 2024

According to Dr William Makis ([source](#)):

*Patient: 93 year old man with esophageal cancer (distal esophagus), sent home on hospice to die. Her dad took 3ml (300mg) of Safeguard (Merck) **Fenbendazole** once a day, 3 days on 4 days off, from July 30, 2023 until Oct. 10, 2023 when he was declared cancer free on follow-up scans. That's 2.5 months on what would be considered a fairly low dose of **Fenbendazole**. The liquid may absorb better than pills or powder.*

He was terminal. They sent him home on hospice to die.  
Cancer was at the end of esophagus and top of his stomach.  
He was literally dying when they sent him home. He was bleeding out through his bowels... he was incoherent... he was not eating. I bought a liquid form of the medicine and gave it to him 3 days on, 4 days off. No other meds.  
He had an appt w the oncologist. His cancer is gone 🙏❤️

48w Like

65 🍷👍🙄



Vanessa Sifuentes

👤 Daylene Martinez what was the liquid form you gave him?

48w Like

2 👍



Daylene Martinez  
Vanessa Franco



Daylene Martinez

October 18, 2023 · 🌐

Vanessa Franco

4 👍



48w Like 2

Daylene Martinez  
Dianne Metro Turner 3mL once a day for 3 days weekly

48w Like Edited 3

Dianne Metro Turner  
Thank you! Did you give him anything else In addition?

48w Like

Daylene Martinez  
Dianne Metro Turner no i didnt. Only for him to eat a clean diet ...

48w Like

Eleni Chris  
🔍 Daylene Martinez did you mix it with anything and with food when he took it ?  
Is he on a maintenance dose now ?

48w Like

Daylene Martinez  
Eleni Chris did not mix it. Just gave orally w a syringe.  
He is still on it for maint.

48w Like 3

Aida Mahalbasic  
🔍 Daylene Martinez how long can you take this for? 3mL 3x a week for how long?

48w Like

Daylene Martinez  
So... july 30th was his very first dose. Last tuesday he was given results that his cancer is gone... he's still taking it. He's gained 10 lbs. His sight came back. He can drive, walk, tend to his yard... ...

48w Like 25

neart w surgery...

48w Like 2

Daylene Martinez  
Peggy Schlayer Peggy Schlayer i bought it on Amazon. thats the only thing he took was the fenbendazole. I understand your feelings. I was the same which is why i gave it one last shot w this. I hope it works for you and for others...

48w Like Edited

Peggy Schlayer  
☑ Daylene Martinez each day for 3 days then off for 4?

48w Like

Daylene Martinez  
Peggy Schlayer yes

48w Like

Stephanie Maynez  
☑ Daylene Martinez you didn't pair with anything else? ...

48w Like

---

Daylene Martinez  
☑ Stephanie Maynez no... i didnt. I quickly bought it and gave it because he was dyingw no time to spare 😞

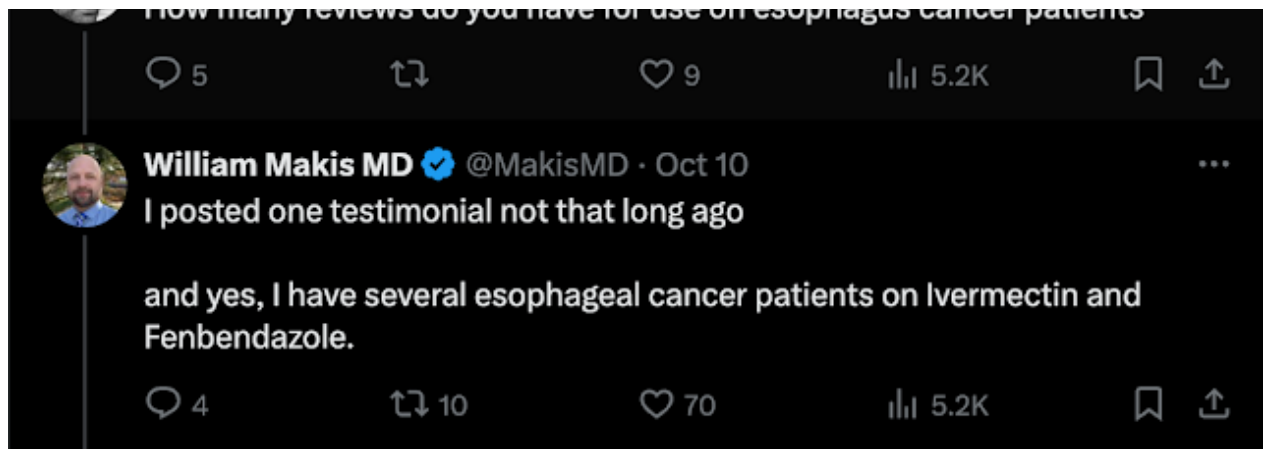48w Like 2

Dani Rowland Woytek  
☑ Daylene Martinez I think we expect instant results and sometimes it's a months long process. I take tons of things just to support my body's natural defenses given everything we are combatting with our food and water and air supply. I feel like we have to all be on our toes against what they might throw at us ...

48w Like

Daylene Martinez  
Dani Rowland Woytek yes... understandable... i was losing my dad quickly and i was scared, wondering if it would work... i prayed over it and decided to give it a shot. It was do or die literally for my dad... it was a horrifying experience. i love to share because someone else's life could be saved... I'll write out the story soon and post.

48w Like 5



Source: Dr William Makis ([X/Twitter](#))

## 9. Endometrial Cancer (4 cases)

Dr. William Makis [shared on X](#) (Twitter) in March 2025:

IVERMECTIN and **FENBENDAZOLE** Testimonials - ENDOMETRIAL Cancer - Four patients from Canada, USA and Germany respond. This is also a world's first!

I had a pile of good responses from my Endometrial Cancer patients so I thought it would make sense to put some together for a short article.

Summary: I have seen Stage 4 Endometrial cancers respond to both Ivermectin and **Fenbendazole**.

In this article I present four cases:

Case 01: 88 yr old Female (Germany) Stage 4 Endometrial Ca, on Fenben CA19-9 dropped from 800 to 90, added Ivermectin and CA19-9 dropped to 80. That's 90% decrease in CA19-9 Cancer marker.

Case 02: 83 yr old Female (Canada) High Grade Serous Endometrial Ca Stage 4, on Ivermectin 1mg/kg/day and Fenben 888mg/day, omental metastasis decreased in size after 2 months.

Case 03: 63 yr old Female (USA) High Grade Serous Endometrial Cancer, had surgery in Sep.2024, on Ivermectin 1mg/kg/day and **Fenbendazole** 888mg/day, "Cancer Free" with negative PET/CT in Jan.2025 after 5 months.

44, after 3 months.

The use of Ivermectin and **Fenbendazole** in Endometrial Cancer has never been published, so my Ivermectin Cancer Clinic is breaking new ground here.

There is one paper that describes Ivermectin inhibiting the WNT pathway, which is key in the proliferation and growth of certain cancers including ENDOMETRIAL.

2014 Melotti et al: The river blindness drug Ivermectin and related macrocyclic lactones inhibit WNT-TCF pathway responses in human cancer. "A variety of sporadic human cancers have been found to harbor hyperactive canonical WNT signaling"

"Other cancers also show an active canonical WNT pathway; these include carcinomas of the lung, stomach, cervix, endometrium, and lung as well as melanomas and gliomas"

"We report that Ivermectin inhibits the expression of WNT-TCF targets"

"Ivermectin inhibits the proliferation and increases apoptosis of various human cancer types"

"In vivo, Ivermectin selectively inhibits TCF-dependent, but not TCF-independent, xenograft growth without obvious side effects"

"Given that Ivermectin is a safe anti-parasitic agent used by > 200 million people against river blindness, our results suggest its additional use as a therapeutic WNT-TCF pathway response blocker to treat WNT-TCF-dependent diseases including multiple cancers."

This is why I can often succeed where the top Cancer Centers in the United States fail. Oncologists don't look at Ivermectin research. In fact, they do everything to avoid it. It's not that they don't know. They don't want to know.

Yes, some of this Ivermectin research is obscure, not easy to find, and not easy to read. But it's there.

Endometrial cancer responds to Ivermectin, and we have an idea why (Ivermectin blocks a key cancer proliferation pathway called the WNT pathway that is active in Endometrial and Cervical cancers).

See "Esophageal and Stomach (Gastric) Cancers" (above)

## 11. Head and Neck Cancer Success Stories (3 cases)

### Case 3: 71 year old Canadian man with aggressive Stage 4 Oropharynx cancer (February 2025)

Dr William Makis shared on [X/Twitter](#):

IVERMECTIN & FENBENDAZOLE Testimonial - 71 year old Canadian man with aggressive Stage 4 Oropharynx cancer sees hope and dramatic tumor shrinkage.

This patient was really not doing well on conventional radiation and chemotherapy, until he came to me...

71 year old Canadian man with aggressive Stage 4 Oropharynx cancer, progressing with lung metastases and not doing well with conventional treatments.

His Canadian oncologists couldn't get the cancer under control.

#### TREATMENT:

From October 2024 we started:

**Ivermectin 40 to 80mg a day** (he struggled but really tried to get the dose up)

**Fenbendazole 1000mg a day, 6 days a week** A few weeks later oncologists started: **Keytruda** RESULTS: CT Jan.20, 2025:

"On palliative systemic therapy"



A bit over 3 months on Ivermectin 40-80mg and Fenbendazole 1000mg 6 times a week.


**Oropharynx primary tumor down from 4.0cm to 3.2cm. Right parotid mass shrunk 71% from 5.8cm to 1.7cm !! Laryngeal soft tissue mass is GONE. Cervical adenopathy shrunk 31% from 1.6cm to 1.1cm. !!**


This was an extremely challenging case of a Stage 4 Cancer patient who was deteriorating rapidly after radiation and conventional chemotherapy I believe we've turned things around beautifully in a way his Canadian Oncologists simply couldn't'. So far from what I'm seeing, Head and Neck cancers are responsive to Ivermectin/**Fenbendazole** or Ivermectin/Mebendazole, either will work!


• Ivermectin and fenbendazole Yahoo/0 - DON... ☆

---



  Wed, Aug 14, 2024 at 2:53 p.m. ☆


**From:**   
**To:** makisw79@Yahoo.com



Looking to purchase ivermectin.And fenbendazole. Have been using horse liquid. Two months at 50 ml n lymph node has increased in size a small amount as well as spots on lung small increased. I messaged u on  and would love to have a consult if at all possible. Need to make a decision about doing immunotherapy, which husband doesn't wish to do. So thinking of ivermectin and your protocol of fenbendazole. Has had radiation n chemo for **head and neck cancer. Spread to lungs.** Appreciate any help you can give and really appreciate all you have been doing to protect people from all the evil in our health system.  
Sent from my iPhone

• Ct Scan Oct 24.  Yahoo/0 - DON... ☆

---

  Mon, Oct 28, 2024 at 4:07 p.m. ☆

**From:**   
**To:** Dr Makis

I have included a recent CT scan.  
 is going to start immunotherapy this week given the progression of his disease. He has lots of thick mucus that he struggles to cough up. We have started w mucinex and manuka honey to try n manage it. Have also reduced the ivermectin to 40 from 50 as he feels too dozy to even drive. Will try to increase it back up if you feel this is an important part of protocol. Do you recommend any other changes to his supplements?  
Look forward to hearing from you.  
Thanks 

PALLIATIVE SYSTEMIC THERAPY. ASSESS FOR TREATMENT RESPONSE/DISEASE PROGRESSION. \*\*\*JANUARY 20-24, 2025\*\*\*

Salivary glands: There has been a significant decrease in the size of the RIGHT parotid mass. The mass is difficult to discretely identify at present but I suspect measures approximately 1.7 x 1.0 cm (previously 5.8 x 3.2 cm). The LEFT parotid gland is normal. The submandibular glands are normal.

Floor of mouth and tongue: There does appear to be residual tumor in the tongue although this is difficult to accurately measure on CT. As an estimate, the area of abnormality measures approximately 3.2 x 2.7 cm (previously 4.0 x 2.9 cm).

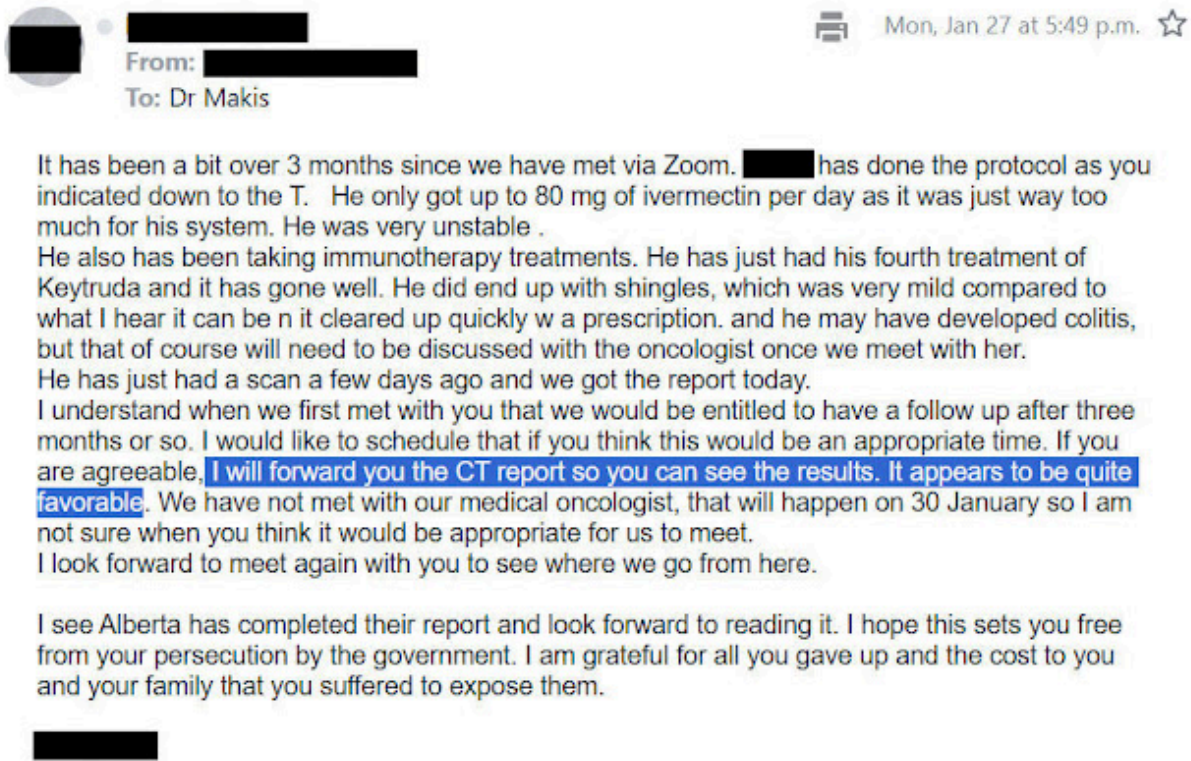
Laryngeal apparatus: There is some residual thickening of the laryngeal soft tissues on the RIGHT at the level of the tracheal cartilage but this is significantly decreased from previous and a measurable mass is not identified. Tracheostomy with tracheostomy tube in situ.

Thyroid gland: Normal

Cervical adenopathy: The level 2A lymph node previously seen on the LEFT has decreased in size from 1.6 x 1.3 cm to 0.8 x 1.1 cm.

#### IMPRESSION:

1. Significant decrease in the size of the RIGHT parotid area mass. The mass is currently difficult to differentiate from the parotid gland but likely measures approximately 1.7 cm (previously 5.8 cm).
2. Some residual thickening on the RIGHT side of the larynx to the level of the thyroid cartilage but this is significantly improved from previous with no measurable mass remaining.
3. There is residual ill-defined soft tissue thickening in the region of the RIGHT parapharyngeal fat and surrounding the RIGHT common, internal and external carotid arteries.

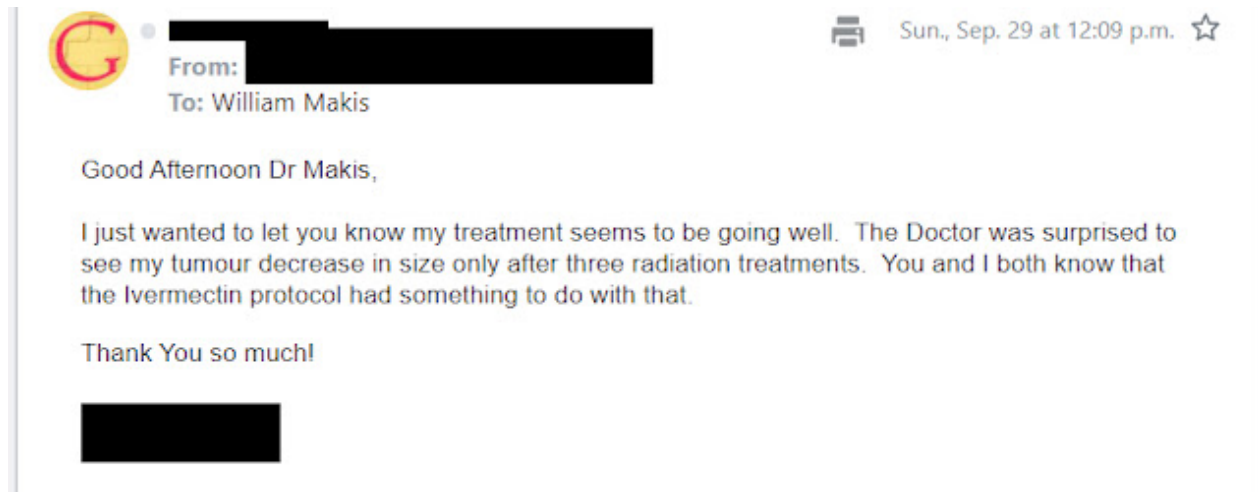


## Case 2: Head & Neck Squamous Cell Cancer

According to Dr William Makis (X/Twitter):

*IVERMECTIN & FENBEDAZOLE Head & Neck SCC Cancer testimonial*

*For those who proceed with conventional chemotherapy or radiation therapy - you should know that you will get much better results combining with Ivermectin & Fenben. The results will often surprise the Oncologist!*



### Case 1: Oral cancer (Squamous cell carcinoma), February, 2023

Condition: Oral cancer (Squamous cell carcinoma)

I was diagnosed 11/2/2022 with oral cancer on base of lower gums and on 11/5/2022, I start taking:

- Merck brand **fenbendazole** liquid goat dewormer 3ml a day (also equal 1/2 teaspoon) for 5 days a week.
- Doctor's best brand: curcumin phytosome 500mg for 7 days a week.
- Now brand: ginger root extract 250mg for 7 days a week.

Went to my ENT doctor and he examined and scheduled surgery for 1/27 2023, (still taking fenben all the time) after excision of skin lesion it was sent to pathologist, the result came back – no cancer!!!

Which of the protocol components did you use? **Fenbendazole**, Curcumin, Other

Other supplements used: Curcumin phytosome 500mg– ginger root extract 250mg

Which conventional treatments did you do? Surgery

## 12. Kidney Cancer Success Stories (8 cases)

Dr. William Makis **shared on X** (Twitter) in March 2025:

Do you think Renal Cell Carcinoma can be beaten? Most doctors will tell you it can't. Well, they're wrong.

Of course, your local friendly mRNA Vaccinated Oncologist has no chance to even contemplate this.

Story: 68 year old man with Stage 4 Clear Cell Renal Cell Carcinoma and lung metastases reached out to my Ivermectin Cancer Clinic.

Did a 3 month protocol of :

- Ivermectin 2mg/kg/day
- **Fenbendazole** 888mg/day
- CBD Oil 25mg/day
- Melatonin 120mg/day

RESULTS: Largest lung metastasis shrunk from 1.3x0.7cm to 1.2x0.3cm.

According to Grok, that's a reduction of 60-70% tumor volume.

Another lung nodule shrunk 0.7cm to 0.6cm, a reduction of 37% tumor volume.

No chemo. No radiation. No immunotherapy.

**Case 1,2 and 3: Three patients with different primary kidney related tumors demonstrated complete response (CR) after receiving **FenBendaZole** (FBZ) therapy.**

Despite multiple anecdotal stories and news outlet reports for its efficacy in treating metastatic cancer, the clinical literature behind utilizing FBZ (**fenbendazole**) as a potential anti-neoplastic agent remains nonexistent. Existing scientific studies have primarily studied its mechanism of action through the use of animal models. In a study published in **Clin Oncol Case Rep** (2020), researchers from Stanford describe three cases where patients achieved **complete responses**, including two who experienced progression after multiple lines of therapy, when FBZ was used alone or in combination with standard therapies.

can be as an anti-oncogenic agent and merits further investigation.

According to the authors:

*Prior studies have demonstrated cancer response to immune checkpoint inhibitors such as nivolumab as a third-line agent in mRCC (metastatic renal cell carcinoma). The duration of therapy was often much longer requiring a median therapy duration of 6 months with 24% overall response rate in third-line treatment. It is possible that our first patient with mRCC would have achieved a significant response to nivolumab alone without FBZ. However, given the complete radiologic response on only 1 month of immune checkpoint inhibitor therapy, it also seems likely that FBZ played a notable role in inducing remission. This is supported by the fact that our patient has remained in extended remission while only on FBZ for nearly a year without further administration of immune checkpoint inhibitor therapy.*

#### **Case 4: July, 2022**

Husband diagnosed 7/19/21

Stage 4 Metastatic Clear Cell Renal Carcinoma (aka Kidney cancer).

Surgery 8/2/21 left radical nephrectomy with complications and have colostomy

9/2/21 Start Opdivo

10/2021 colostomy reversal

11/2021 land in ER with sepsis (unknown origin) and have surgery

11/2021 Start Yervoy in addition to Opdivo (and FenBen)

11/2021 (just before Thanksgiving), doctor said "let's see if you can make it 5 weeks" when husband asked about prognosis

12/21 Travel to NYC to spend what my husband believes is his last Christmas

1/3/21 ER visit due to lack of lucidity

1/22 Start Cabo (have been off FenBen because of all the hospital visits)

5/22 – Cancer is shrinking some totally gone – off nearly all pain meds. Doctor says he’s never seen this much progress in such little time.

6/22 – Cancer is still shrinking – off almost every pain med (1 10MG Oxy a day)

7/22 – Cancer still shrinking!! PTL

Not doing anything crazy

### **Case 5: November, 2021**

In the beginning of 2021 I was diagnosed with stage three kidney cancer followed by stomach cancer a few months after.

I did not want to go for any radiation or chemo knowing the adverse effects it will have on my body. I jumped onto a **fenbendazole** course immediately which I followed for a good 6 months and got the incredible news that I am completely cancer free!

### **Case 6: December, 2021**

In 2016 I was diagnosed with stage 4 cancer in my kidney and abdomen alongside a secondary diagnosis of follicular lymphoma. The Oncologist predicted that if I am lucky I will have 6 months left to spare.

I declined any medical help that came my way and decided with dedication and faith to take the natural path to healing from the very beginning of my cancer journey.

It has been a challenging journey for me the last year and I thought I might not make it at one point. But, then, everything started to change and my symptoms were fading slowly but surely from using various methods and eventually ended up taking **fenbendazole** and following the protocol religiously. I started off on a dose of 150mg and kept on increasing it from there over a period of four months. I showed symptoms when I hit the 600mg dosage and was very concerned that it might not be the best approach and even though I kept on increasing the dose over a reasonable amount of time and took a break off of it for a couple of days before I would continue on it again.

Over the last month the swelling in my face seems to have decreased and I don’t experience

say!

I still have a long journey to walk, but I am more motivated than ever and I attribute all the success to the use of this protocol and encourage everyone to give it a go! Do not lose hope.

### Case 7: Renal Cell Carcinoma (Stage 4) - July 2024

Re: Survived stage 4 clear cell renal cancer for 22 yrs no reoccurrence or treatment

Yahoo/00 - LO... ☆

because I lived for over 22 yrs not worrying about stage 4 cancer (less stress) I was forced to get the job to keep my job in October 21 by the winter of 2021 pressure and strange feelings in my side always had strange feelings since surgery so put it off till late fall of 2022. All hell broke loose in early 2023 went for radiation treatment June then met Dr [REDACTED] on Sept after CT scan he wasn't happy with how much cancer had shrunk thought it should've been more reduction in tumour. Went for scan in January and things were bad I was in a lot of pain tumour was back to its original size and spreading into my left thigh buttock and groin. Spoke with Dr [REDACTED] he said nothing more he could do for me would have to wait till likely early April as Cross chemo was very busy! So I spoke with my Dr told him I was taking matters into my own hands wasn't waiting around doing nothing till April he set me up for a scan before going to hear about chemo options in late March. Started taking blend of Mushrooms and started high vitamin c magnesium made some changes in my diet and got in touch in a round about way with [REDACTED] started taking 18 mg of ivermectin daily 3 apricot kernels I was on ivermectin 19 days went for a CT scan March 25th results were amazing a very substantial reduction in tumour and pain and mobility much better! I am still taking ivermectin and also Fenbendazole plus mushrooms and vitamins. I will be going for CT scan June 17th this was set up by Dr [REDACTED] is he will be having a phone call with me from Cross to review results. This is short version and I hope to be able to discuss with you for future recommendations also I have been helping others with their situations as much as possible sharing my story which I feel is so far very successful. Thank you so much for taking the time to read this. Looking forward to hearing back from you? Have a Great Day!

Good morning Dr Makis had a good results from my last scan tumour still shrinking, a lot less nerve pain. Dr [REDACTED] was impressed suggested we move scan to 4 months so next scan scheduled for October. I have added Lions mane mushroom to help with nerve pain in last week seems to be making a huge difference with pain sleeping much better! I have been contacted by a young man's family he has just been diagnosed with Lymphoma hope to get more info from him to possibly share with you for possible treatment protocol his aunt has come for ivermectin going to start on that for now. Any suggestions would be greatly appreciated! Have a Great Day!

Source: [William Makis, MD \(X.com\)](#)

## 13. Liver Cancer Success Stories: Fenbendazole

### Case 1: September, 2021

I was given less than two years to live in 2020 when I was diagnosed with stage 4 (metastatic) HCC (HepatoCellular Carcinoma) liver cancer. I received radiation directly onto the tumors and went for immunotherapy which did not bring any improvement to my state I was in. My wife and family did research and came across the [fenbendazole](#) protocol. I had nothing left to lose, so I decided to give it a try.

### Case 2: September, 2021

In 2021 the doctor discovered a tumor growth at the end part of my colon. The test results

active person for almost all of my life, taking my vitamins on a daily basis as I start my day – I never thought that something like this could ever happen to me.

After I made peace with what was happening inside my body, I gathered myself and started seeking for the best possible advice/guidance out there on any alternative approach other than putting my body through all this stress. I managed to start a protocol on: 1mg FECO, RSO oil which I used on the daily, and supplements at night along with some juicing which includes soursop & green tea, 20000mg Vit D, 5000mg Vit C & Vit K, 800mg grape seed extract, 2100mg ashwagandha, 1950mg curcumin with ginger & black pepper, sea cucumber extract, and 2000mg **Fenbendazole** on a daily basis (½ in the morning; ½ at before bed).

I never told my doctors about this and continued with treatment alongside the use of this protocol. A few months has passed since I started this journey and I received my results again later that year, showing no presence of any tumor. It completely vanished into thin air! After only four chemo treatments the doctor could not comprehend how the cancer just managed to disappear like that, and so quickly too – considering the time period for chemo to work to be proven to take much longer before it actually starts working.

## 14. Lung Cancer Success Stories (13 Cases)

**Case 13: IVERMECTIN and FENBENDAZOLE Testimonial - Stage 4 Lung Cancer patient in India with metastases to brain, liver and bones, sees dramatic recovery including "complete resolution" of liver & bone mets! (Jan 2025 update)**

Case testimonial from Dr William Makis ([X/Twitter](#)):

"IVERMECTIN and FENBENDAZOLE Testimonial - Stage 4 Lung Cancer patient in India with metastases to brain, liver and bones, sees dramatic recovery including "complete resolution" of liver & bone mets!

An International story you're going to love!

Adarsh contacted me in early September 2024 about his dying father in India who had Stage 4 Lung Cancer with metastases everywhere including brain, liver, bones.

"doctors has given some months to live".

So I suggested an Ivermectin/**Fenbendazole** Protocol - something simple, yet powerful:

Ivermectin 1.5mg/kg/day

RESULTS:


PET Scan of 27 November, 2024:

- complete metabolic resolution of liver and bone metastases (!)
- decrease in size and number of mediastinal lymph nodes
- decrease in size of brain metastases (!)
- decrease in lung lesion.

There are people who claim Ivermectin and Fenbendazole don't cross the Blood Brain Barrier. Well, they're wrong!"

(No Subject) Yahoo/04 - TES... ☆

---


 **Adarsh** [redacted] Mon, Jan 6 at 10:57 p.m. ☆  
From: adarsh [redacted]  
To: makisw79@yahoo.com

Hi @dr makis  
This is Adarsh [redacted] from India, my father had diagnosed with stage 4 lung adenocarcinoma metastasized to brain, liver, bone, mediastinal lymph nodes, asper your suggestions i gave him 1.5mg/kg ivermectin and 444mg fenbendazole for 3 months. In the pet scan of 27 november, complete metabolic resolution of liver and bone is shown, decrease in size and number of mediastinal lymph nodes, decrease in size of brain mets, decrease in lung lesion.  
Thankyou, i will inform you with reports when it gets cleared from body

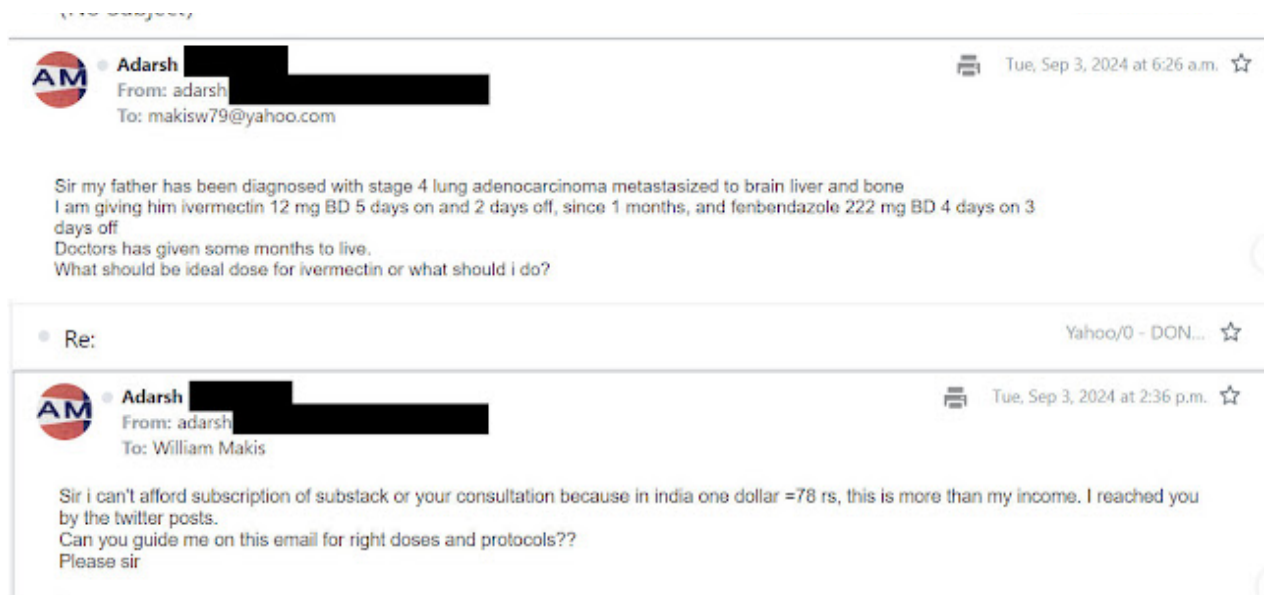
← ↶ → ⋮

Re: Re: Yahoo/Sent ☆

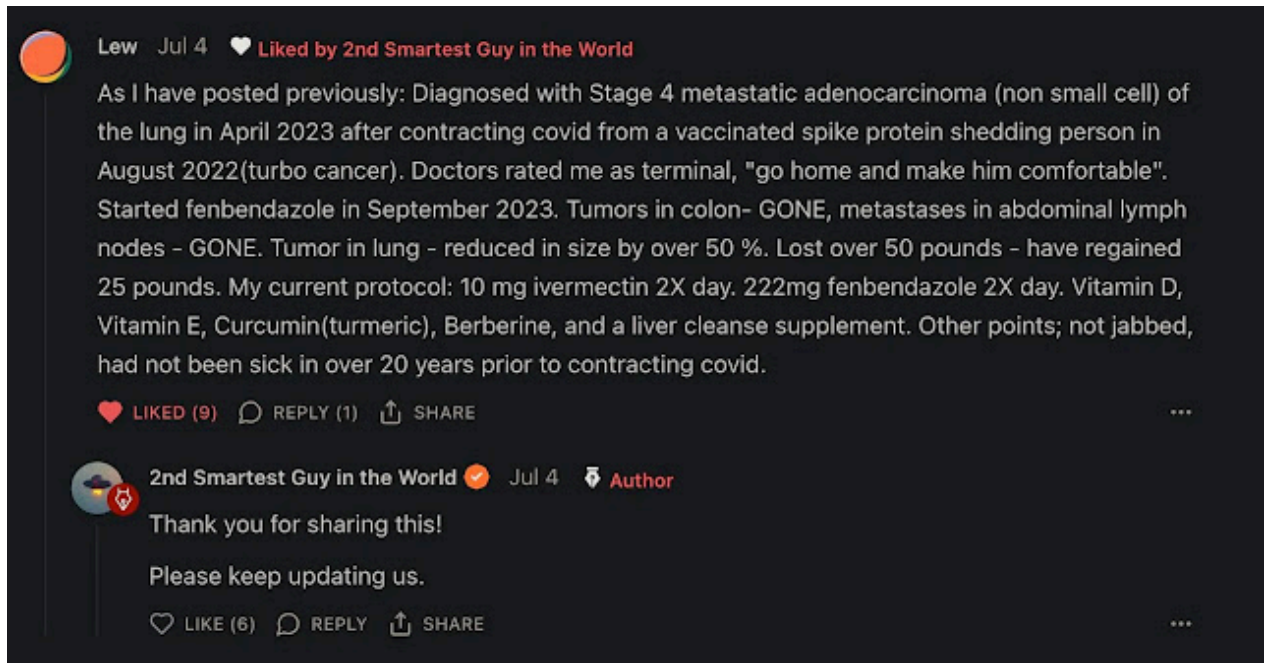
---

 **William Makis** Tue, Sep 3, 2024 at 11:18 p.m. ☆  
From: makisw79@yahoo.com  
To: Adarsh [redacted]

Stage 4 Lung cancer, give Ivermectin at least 1mg/kg/day  
so if he is 60kg, it would be 60mg per day. If he tolerates it, push it to 90mg.  
Fenbendazole also push to 444mg/day and if liver function is OK, 888mg/day  
William



Case 12:



source: <https://substack.com/home/post/p-155091883>

An update on my Metastatic Stage 4 non small cell adenocarcinoma of the right lung. Just had a CT last week. No sign of tumor in lung. However, I have a lot of scar tissue in my lung. My pulmonologist called it "a crust between the lung and chest wall". I wonder if the Covid I contracted from being exposed to spike proteins caused this?(rhetorical question) This affects the ability of the lung to expand and affects lung function(i.e. shortness of breath after exertion). Supposedly there is nothing that can be done. However, there are certain natural supplements which break down fibrin(main component of scar tissue). It will take a while but I believe the body, with the right nutrients, can mend itself. One final point. I am not totally cancer free(cancer markers still elevated) but I have come a long way from being diagnosed a year and a half ago. Fenbendazole works.

❤️ LIKED (14) 💬 REPLY (2) 📤 SHARE

### Case 11:



Katarina Christoforou Lex Naturalis Jun 15 ❤️ Liked by 2nd Smartest Guy in the World

I was diagnosed with metastatic NSCLC in January 2024, as a reader of this substack I started on the Joe Tippens protocol. I was offered Chemo and Immunotherapy (Pembrolizumab). My Oncologist is the shittiest doctor going - Mr Berliti at Exeter RD&E. He told me nothing about the medicine I agreed to receive, and the research was entirely up to me. He told me Immunotherapy had no side effects. He also told me I couldn't record the consultation. Just as well I had a spare phone, so he saw me turn off one but not the other. I said no to Chemo, straight off the bat.

So I would like to tell you what a success the protocol is, but the NHS are so shit they are not reviewing my cancer in a reasonable manner, meaning they have not scanned me since January, so I have no idea what the cancer is doing.

I have stopped coughing up blood, so as that was the only troubling symptom I reckon things are going well. I mean I'm not dead yet, and the only symptom I had has gone away. Sounds good right? I mean I can't do anything about the NHS, but not being dead is the goal, so thumbs up to the protocol I think...

❤️ LIKED (13) 💬 REPLY (1) 📤 SHARE



2nd Smartest Guy in the World 🏆 Jun 15 🗑️ Author

Absolutely incredible.

I really hope you can get a scan soon and update us sooner, rather than later.

❤️ LIKE (4) 💬 REPLY (1) 📤 SHARE

source: <https://substack.com/home/post/p-155091883>

### Case 10: IVERMECTIN and FENBENDAZOLE Testimonial - 40s year old California Man with Stage 4 Lung Cancer (Jan 2025 update)

Case testimonial from Dr William Makis (X/Twitter):

improvement in 3 months!

Another wonderful story for you:

40s year old California man (who had three Pfizer COVID-19 mRNA Vaccines), was coughing for months, and was diagnosed with an unexpected Stage 4 Lung Cancer (NSCLC) metastatic to numerous lymph nodes and pleura, with a pleural effusion.

We started an aggressive protocol:

- Ivermectin 1mg/kg/day increasing slowly to 2mg/kg/day (high dose!)
- Fenbendazole 888mg/day
- Oncologist also started Tagrisso (Osimertinib)

3 Months Later:

Primary lung tumor reduced in size from 3cm to 2cm.

Pleural effusion resolved completely (!) Gained 15 pounds of weight from his lowest before he started the protocol. These are very significant improvements!"

----- Forwarded message -----  
From: [REDACTED]@gmail.com>  
Date: Fri, Jan 3, 2025 at 3:14 PM  
Subject: Fwd: ivermectin, fenbendazole  
To: William Makis <makisw79@yahoo.com>

Dear Dr. Makis,

Hope you are having a blessed New Year so far!

Thank you again for helping my friend [REDACTED]. Because of the protocol you've put him on, he's already seen a great reduction in the tumor size in his lungs (from 3cm to 2cm) from his last scan, as well as lung fluid completely resolving! He's also started gaining weight by about 15 lbs from his lowest before he started the protocol. Thank you for your lifesaving work.

I've seen the testimonies of the Australian Cattle Dog recovering from cancer. Over Christmas, my brother [REDACTED] gave me the unfortunate news that his dog, [REDACTED], who also happens to be an Australian Cattle Dog, has lung cancer. I'm connecting him with you here so that perhaps he could consult with you for the sake of [REDACTED].

Would he fill out the consent form as normal and would the consultation work in the same way as you've previously described below?

Thank you for all your life saving work. I'm grateful to the Lord for you - for the sake of my friends and my family.

Blessings,  
[REDACTED]

**William Makis**

From: makisw79@yahoo.com

To: [REDACTED]

Sun, Oct 13, 2024 at 6:36 p.m. ☆

Hi [REDACTED]

Hopefully the Ivermectin will lower the HBV levels

You can take Tagrisso with the Ivermectin Protocol - you will have better outcomes

William

On Sunday, October 13, 2024, 06:36:09 p.m. MDT, [REDACTED] wrote:

## Cancer Consultations

Yahoo/0 - DON... ☆

From: [REDACTED]  
To: makisw79@yahoo.com

Tue, Oct 1, 2024 at 6:00 p.m. ☆

Dear Dr. Makis,

A friend of mine, [REDACTED], told me about your cancer consultations for alternative treatments involving Ivermectin and/or Fenbendazole, and I am very interested.

Could you please let me know what information I would need to provide prior to the consultation session?

I recently completed a CT scan, a biopsy, and a PET scan. The CT scan shows a 3-cm nodule in the upper lobe of my left lung. I should be getting the results of my biopsy and PET scan tomorrow. I had two COVID vaccine and one booster shots.

I will send back the signed consent form shortly.

Best regards,

[REDACTED]

## Re: ALTERNATIVE MEDICINE PROTOCOL (Dr.Makis)

Yahoo/0 - DON... ☆

From: [REDACTED]  
To: William Makis

Sun, Oct 13, 2024 at 6:36 p.m. ☆

Dear Dr. Makis,

I hope you are doing well. Thank you for the Fenbendazole and Ivermectin protocol.

I really appreciate your commitment to advocating for alternative cancer therapies and your support for medications such as Fenbendazole and Ivermectin, which have demonstrated potential benefits yet frequently face suppression by the pharmaceutical and medical sectors due to financial interests.

I also wanted to share some updates regarding my treatment. Last week, my oncologist requested a brain MRI and blood tests to check my Hepatitis B viral load. The MRI results were clear, but my HBV level has increased to [REDACTED] iu/mg, up from about [REDACTED] in late 2023. At the time of the HBV test, I had been taking Fenbendazole (444 mg daily) for around 10 days. Do you think this is something I should be worried about?

Also, the oncologist recommended that I start taking Osimertinib (Tagrisso). I am considering using the alternative drugs and vitamins you recommended as the primary treatment, with Tagrisso as secondary, but I'm uncertain if the two could interfere with each other. Could you please let me know your thoughts?

Looking forward to speaking with you on Wednesday.

Best Regards,

[REDACTED]

## Case 9: November 2024 - Ivermectin and Fenbendazole for stage 4 NSCLC Lung Cancer

IVERMECTIN and FENBENDAZOLE Testimonial - 40s year old woman with Stage 4 NSCLC (Non Small Cell Lung Cancer) - dramatic improvement after 3 months!

40s year old Stage 4 Lung Cancer Patient in the UK In August 2024, we started Ivermectin 1mg/kg/day and Fenbendazole 444mg/day 6 days on 1 day off

There were some transient visual effects from Ivermectin to overcome in the first few weeks (see messages) But they went away after a few days!

And less need for strong pain medications! 3 month Follow-up Report:

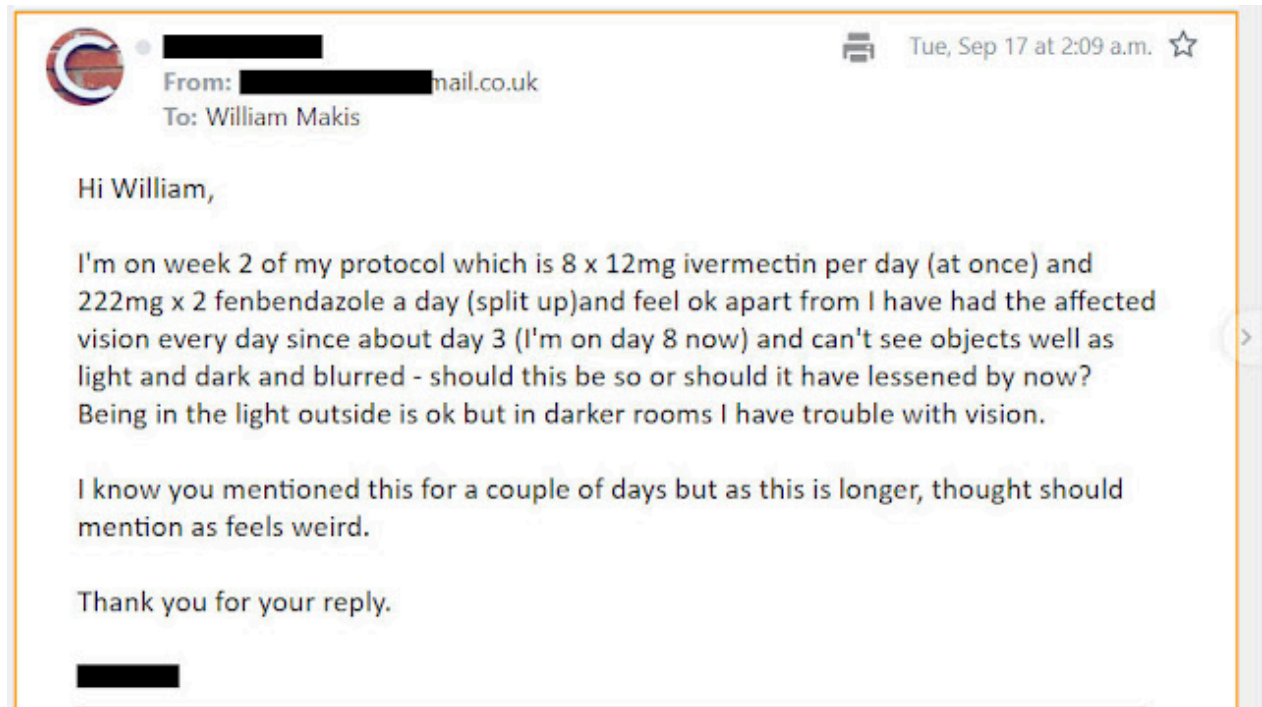
“Cancer is stable and all lesions / tumours have shrunk”

“biggest shrink of all was the one above adrenal gland which has gone from 6cm to 3.6cm!”

“spots on the left lung and liver were so small they were too small to measure”

My Take... It is wonderful to see results like this after only 3 months! Sometimes there are some minor growing pains in the beginning - some transient side effects to overcome (like the visual side effects of ivermectin), but once you overcome them, it's smooth sailing! In this case they lasted about 10 days and then they were gone.

And yes, we did push to get to Ivermectin 2mg/kg/day (substantial dose) and Fenbendazole 888mg/day (moderate dose). Can you imagine a Stage 4 Lung 6cm adrenal metastasis shrinking to 3.6cm and all other lesions shrinking, some disappearing or becoming too small to measure? In just 3 months? Not bad for horse medicine!



Hi William,


So figured good to start back from all the ivermectin and fenbendazole as day 1 dosage tomorrow again and go a bit slower up? What do you think? How do other people manage?

Maybe it is because of the other prescription or pain meds I am taking? Which by the way, I haven't needed to use any of the Oro-morphine liquid for over a week and have stopped taking paracetamol since Tuesday also as not needed - this should be seen as good news right? 😊

Thanks again and I really look forward to hearing from you.

P.S. All side effects have completely gone now.

Re: Patient of Dr. Makis Yahoo/03 - TES... ☆

 Wed, Nov 13 at 8:15 a.m. ☆

From: [Redacted] co.uk  
To: William Makis

Dear William,

I wanted to share some good news with you after receiving my 1<sup>st</sup> scan results back from the oncology team (after 3 rounds of 28 days of Tagrisso tabs).

They are good! The cancer is stable and all lesions / tumours have shrunk. The biggest shrink of all was the one above adrenal gland which has gone from (oncologist here couldn't say exactly but thinks around just over) 6 - 3.6cm! The spots on the left lung and liver were "so small they were too small to measure, maybe a mm or so."

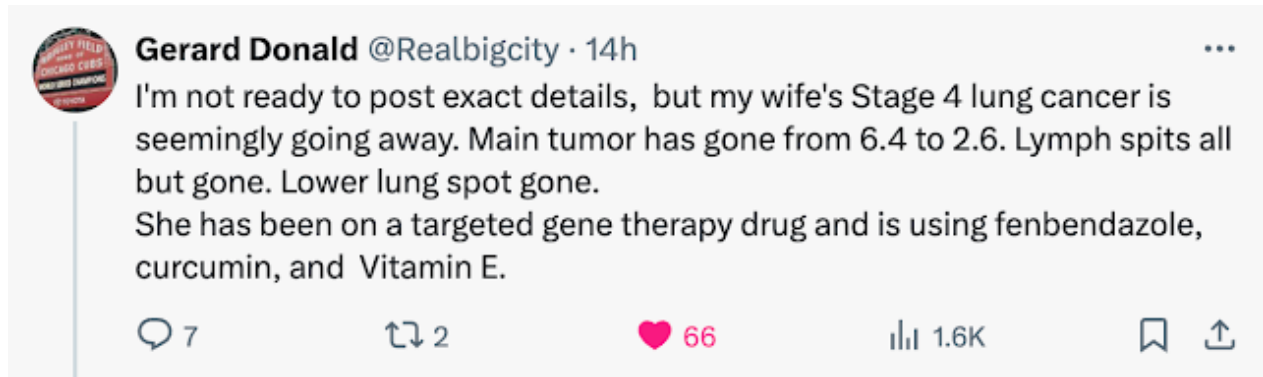
I am happy to continue to take my alternative treatment of course :)

Kind regards,  
[Redacted]

### Case 8: November 2024

Case sharing by Gerard Donald ([X/Twitter](#)):

been on a targeted gene therapy drug and is using **fenbendazole**, curcumin, and Vitamin E.



### Case 7: October 2024 - Ivermectin and **Fenbendazole** for stage 4 Lung Cancer

Case testimonial from Dr William Makis ([X/Twitter](#)):

One of my cancer patients is a woman in her 70s with Stage 4 Lung Cancer with multiple liver metastases. "Less than 7 weeks after initiating the protocol"

Primary Lung lesion LLL 2.9cm to 2.1cm (28% decrease)

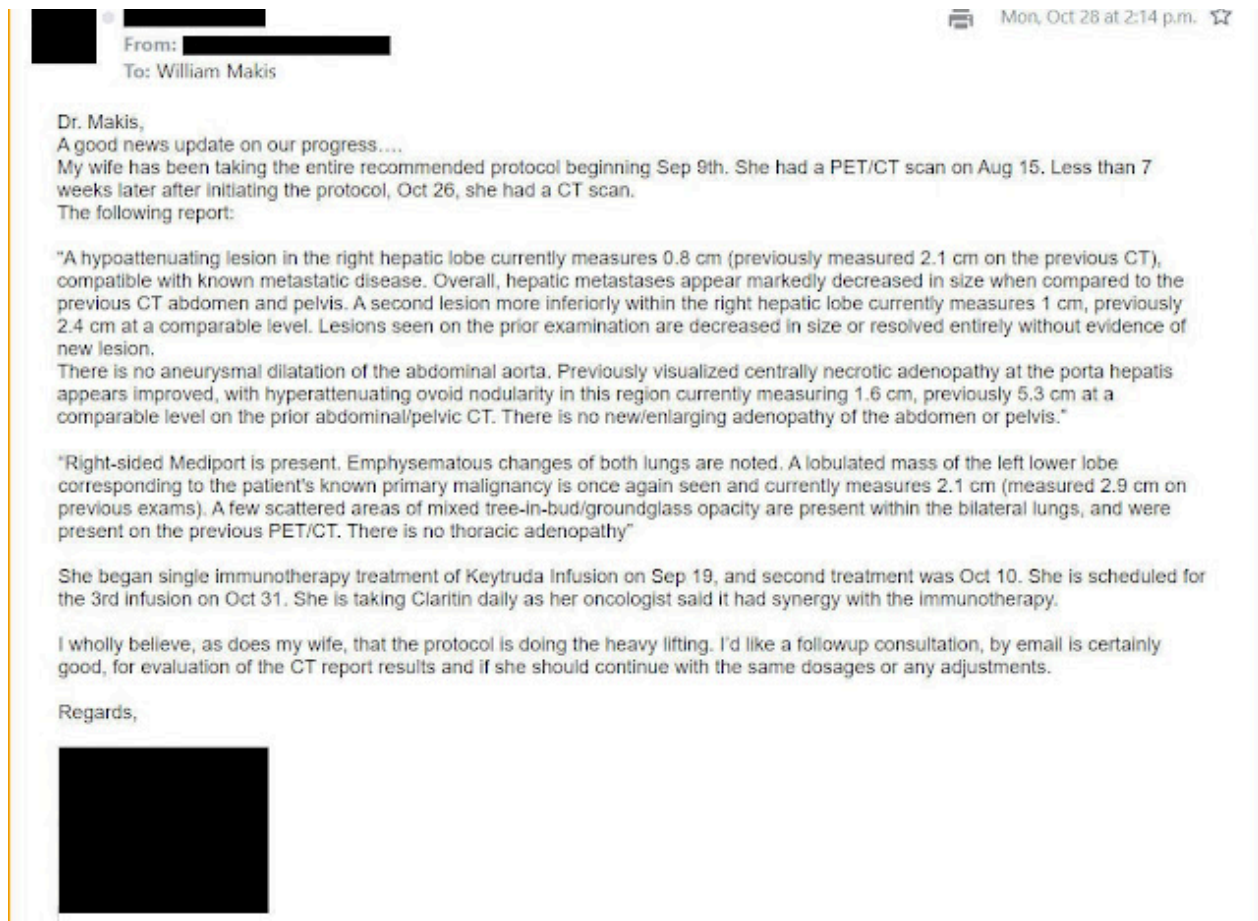Liver at porta hepatis 5.3cm to 1.6cm (70% decrease)

Right hepatic lobe inferiorly, 2.4cm to 1.0cm (58% decrease)

Right hepatic lobe, 2.1cm to 0.8cm (62% decrease)

"Overall, hepatic metastases appear markedly decreased in size when compared to the previous CT"

"I wholly believe, as does my wife, that the protocol is doing the heavy lifting".



## Case 6: September, 2023

Condition: Stage 2 Adenocarcinoma in his upper right lung lobe

In July of 2018, my husband received his first cancer diagnosis. Stage 2 Adenocarcinoma in his upper right lung lobe. Mutations tested. Lobe was removed

July 23, 2018, and he was put on active surveillance, no treatment.

On 11/14/2018, he received his second diagnosis, prostate cancer, adenocarcinoma with metastasis, stage 4, and Gleason score 9. Prostate was removed, followed by 7 weeks of radiation, and put on ADT therapy (Lupron and Xtandi), no chemo. Mutations tested, not favorable, and very aggressive. He is a rare case where cancer didn't show in blood or any scans. To this day, it still doesn't. We can only monitor by symptoms.

He started to progress in symptoms in June of 2022. August of 2022, diagnosed with a 2nd lung cancer, stage 4 adenocarcinoma. Mutation testing repeated, this time, it showed similar

He began treatment on 01/09/2023. We were not given any hope, and they said mutations were not in his favor and that treatment was highly unlikely to do anything, but they offered it anyways saying it would buy him time. They made it very clear he did not have the mutations they were hoping to see, they were hoping it was a mutation that responds favorably to treatment, and he didn't have those.

It didn't make sense, in 1 sentence they stated it wasn't likely to work, but yet it could buy him time?? It is his journey, and he decided to try. 2 chemo drugs, and 1 immunotherapy for 4 treatments spaced 3 weeks apart. Then they dropped 1 chemo and said he would stay on double treatment for up to 2 years, then they would drop to just immunotherapy. He stayed on double for 7 treatments. But his body was worn out. They decided 1 more treatment, and if scans looked good, they would drop the other chemo. But he got sick just before the last double treatment was supposed to happen. It has delayed his scan as well. But it is a viral thing, not cancer related, as far as we know.

Let's get to the good stuff though... People started sending me messages, LOTS of people, asking me if I'd heard of the Fenben Protocol. I started getting these messages in August of 2022, right after his biopsy confirmed a new occurrence. To be honest, I ignored the messages until I got 2 in 1 day in November. I decided ok, I'm going to check this out. I joined the group on December 16th, 2022 and I started tearing into the files. And I started researching, and research led me to a medical sight that leaned very favorably in Fenbens direction. We discussed as to whether to bring it up to oncology, but they had made it clear in the beginning that if we choose to do natural, they would not treat him, so we kept our mouths shut.

He started the protocol at the end of February. His scans on 12/22 and 02/23 showed new masses had grown since the scan in July of 22. But by the next scan on 04/06/2023 many of the masses were still present, but stopped growing. But the masses in his pleura (which is what deemed him terminal) were almost gone! Let me note right here, that by this time, his prostate symptom progression stopped, and then the symptoms resolved.

Next scan on 05/30/2023, pleura masses are now unremarkable, and the other scattered masses still haven't grown any.

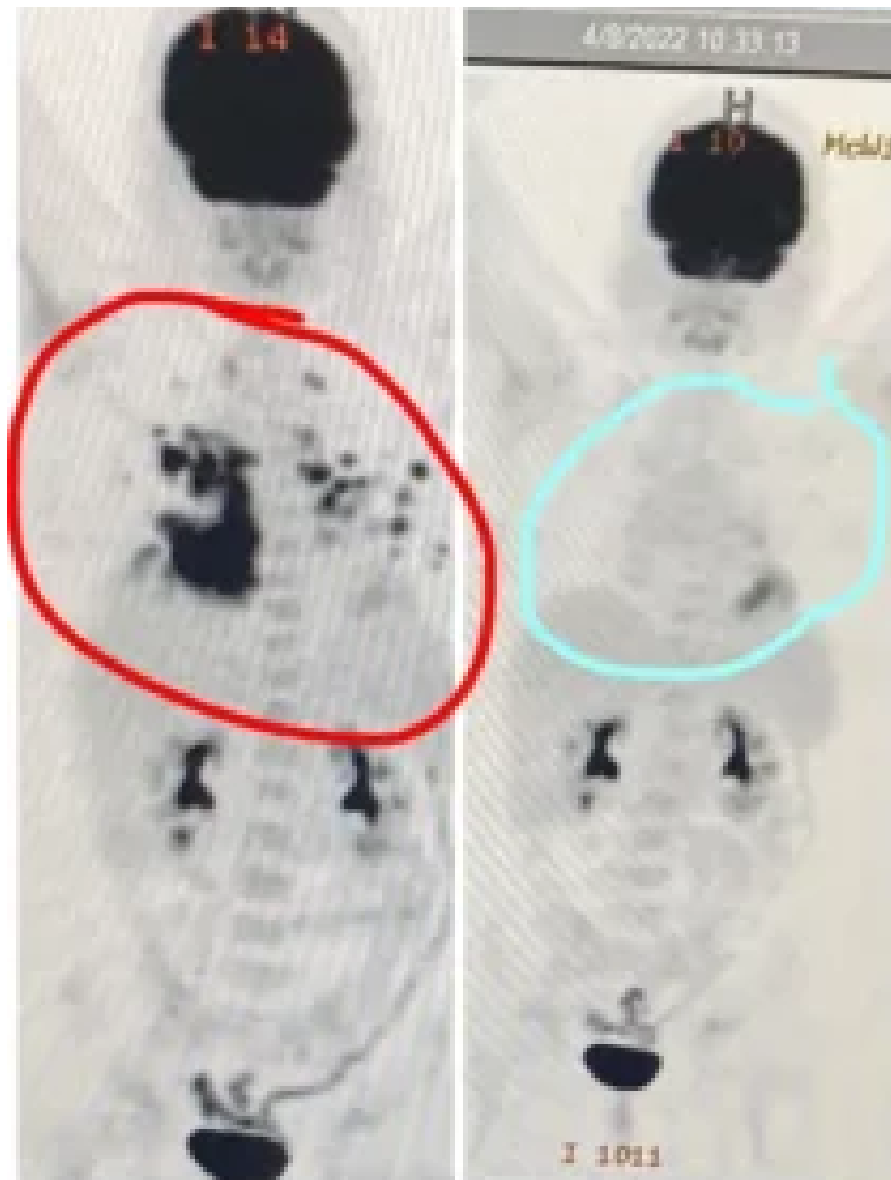Next scan on 07/30/2023, pleura isn't even discussed, no remarks! Dr says they can't see anything there at all! And the other masses remain unchanged, no growth! Whether we simply bought him time, or he's healing, we will take it! But our hope is restored. He's not in pain and he's still his ornery self. And we remain grateful to the community for the knowledge and

**Case 5: July, 2022**

I have stage 4 Adenocarcinoma of the lungs...doctor told me it's not curable. I'm 44 with two teenagers so I don't want to hear that kind of news. Anyway, I was diagnosed in December and by January I received chemotherapy. A friend told me about **Fenbendazole** and I started it immediately. I am now on chemotherapy, immunotherapy, and **Fenbendazole**. After 4 treatments...I had a PET Scan....the scan was remarkable. Many subcentimeters nodules resolved, the two large masses are shrinking, no enlarged lymph nodes in the hilar and mediastinal region. No new growth! I'm hoping this is a good sign.

\*Using **Fenbendazole** 220mg day and night, chemo taxol/Carbo, and Keytruda since January.

Plan to start Vitamin E, Milk thistle for liver, and Turmeric/Curcumin this week.



#### Case 4: July, 2022

They gave my husband 18 months to live in 2019, from having SCLC with no primary tumor. Mets everywhere. He has been doing Joe Tippens protocol before he even started chemo. Chemo didn't work and he is now on Opdivo infusions once a month. We found out he had cancer from 3 fractures on his vertebrae. Went to his brain and that's all gone also. Thank you Joe!! Praise the dear Lord!!

DATE OF EXAM: May 5 2022 10:17AM

AKP 0063 – NM PET/CT SKULL-THIGH SUBQ / ACCESSION # 130564079

bronchus or lung (HCC)

### **Case 3: March, 2022**

In 2020, I was diagnosed with stage 4 lung carcinoma. The Oncologist found a big tumor growing on my left lung along with a massive tumor inside my chest cavity so big that it started constricting my heart arteries.

They started me with radiation right away followed by weeks of intensive chemotherapy, and I got so sick that they had to lower the doses and frequency to half of what they originally had me on.

### **Case 2: November, 2021**

About three months ago my wife was diagnosed with metastatic cancer on her lungs and gave her a 3 months prognosis. She had five aggressively growing nodules.

A friend reached out to me about the **fenbendazole** protocol that she was following at the time. Today my wife came back from a visit to the Oncologist with test results showing a major improvement on the growths – only two small nodules were found! This is truly a miracle and a blessing!

### **Case 1: Small Cell Lung Cancer (SCLC) with Joe Tippens Cancer Protocol (2017)**

Joe Tippens founded the **fenbendazole** protocol after he was told a story about a scientist at Merck Animal Health that had been performing cancer research on mice. The research included injecting different types of cancers into different mice body parts. The scientists discovered, through trial and error, a product in their canine product line, **fenbendazole**, that was batting 1.000 in killing these different cancers in the mice. The scientist was later diagnosed with stage 4 brain cancer and was given a grim prognosis of only three months to live. She decided to try the **fenbendazole**, and after six weeks, showed a clean scan.

Joe Tippens had been initially diagnosed with **small cell lung cancer**. The cancer later spread to his neck, right lung, stomach, liver, bladder, pancreas and tail bone. Like the scientist from Merck Animal Hospital, Joe was told he only had three months to live. In 2017, after hearing the story of the scientist who treated her cancer with a canine drug, Joe decided he was going to do the same. However, in addition to taking the **fenbendazole**, Joe added his own ingredients

## 15. Leukemia (Acute Myelogenous Leukemia (AML) and Chronic Lymphocytic Leukemia (CLL))

2 Case testimonials from Dr William Makis ([X/Twitter](#)):

**IVERMECTIN and FENBENDAZOLE Testimonial - Two blood Cancer Cases: Acute Myelogenous Leukemia (AML) patient becomes "cancer free" and Chronic Lymphocytic Leukemia (CLL) patient improves 1st time in 2 years!**

Case 1:

**AML Patient** diagnosed in October 2024

Immediately started **72mg Ivermectin and 1000mg Fenbendazole 3 days on 4 days off**

Also did 2 rounds of chemo in November and December, and in December added oral chemo pill Venclexta

Results after 2 months of Ivermectin & Fenbendazole:

*"His bone marrow biopsy from December 24th came back clear! His blood work is looking good."*

*"We are so thankful for men like you that are willing to do the right thing in the face of great persecution" 🙏*

=====

Case 2:

**63M CLL patient with a high WBC count in Sep.2022, on "watch and see"**

I didn't go aggressive here, started: **70mg Ivermectin and 500mg Mebendazole:**

Results:

**WBC 16.1 (Oct.2) → 15.6 (Dec.6) → 14.1 (Jan.15)**

On Dec.11 I made a few minor adjustments:

increased from 500mg to 1000mg/day Mebendazole and added 1000mg/day Lactoferrin.

After 2 years of being abnormal, the WBC and Lymphocytes are trending towards normal range (almost there)!

*"It is definitely trending down since beginning the protocol"*

Right now, there is only one peer reviewed publication that has documented the use of Ivermectin in Human Cancer Patients.

Can you guess what the Cancer is?

Leukemia. And it's behind a paywall.

2020 de Castro: "Continuous high-dose Ivermectin appears to be safe in patients with acute myelogenous leukemia and could inform clinical repurposing for COVID-19 infection"

From: [REDACTED]  
To: makisw79@yahoo.com

Fri, Jan 3 at 6:07 a.m. ☆

Good Morning Dr Makis,

First, we continue to pray for you and your family's protection from this unjust prosecution.

Next, my husband was diagnosed with AML in October. We immediately started your protocol and also did two rounds of chemotherapy in November and December. In the December round they added the oral Chemo pill Ventaclexta and an anti fungal voriconazole - he was already taking acyclovir. He almost immediately had hallucinations and confusion so they changed the anti fungal to fluconazole. The hallucinations stopped but the confusion has continued. On the 30th they took him off everything except his amocillin. He continues to take his Ivermectin and Fenbendazole. He also takes a multi, D3, omegas, and dessicated beef liver. The confusion is not clearing up.

**His bone marrow biopsy from December 24th came back clear! His blood work is looking good. They did a lumbar puncture and it came back normal.** Any ideas what could be causing the brain confusion? I can send his tests if that helps at all. We hesitated to ask since you have so much to deal with right now but this confusion is rough. We are so thankful for your protocol. We believe it is the push that allowed a clear biopsy in just 2 months. We are so thankful for men like you that are willing to do the right thing in the face of great persecution.

Best regards,  
[REDACTED]

---

RE: Follow-up success: Leukemia Yahoo/04 - TES... ☆

From: [REDACTED]  
To: William Makis

Tue, Jan 14 at 9:12 a.m. ☆

[REDACTED] has been taking 72 mg of Ivermectin daily. He takes 1000 mg of Fenbendazole on Monday, Wednesday, Friday. We took last week off and started again yesterday. His oncologist is wanting to start another round of chemo next Monday. We are hesitant. They are still encouraging us to do chemo rounds until we can get to a bone marrow transplant. Do you have any thoughts on what direction we should look to go as we continue with the Ivermectin and Fenbendazole?  
[REDACTED]


Hi Dr. Makis,

Month 2 Bloodwork(attached) and no significant change again.  
I did get a 3 day water fast in and added the Lactoferrin and doubled the Mebendazole as suggested.

I will continue with the current protocol, unless you have any changes to recommend.


Thank you,

Re: Follow-up #348 - CLL Improvement - Lymphocytes 13 to 12.5 to 11.3 Yahoo/Sent ☆

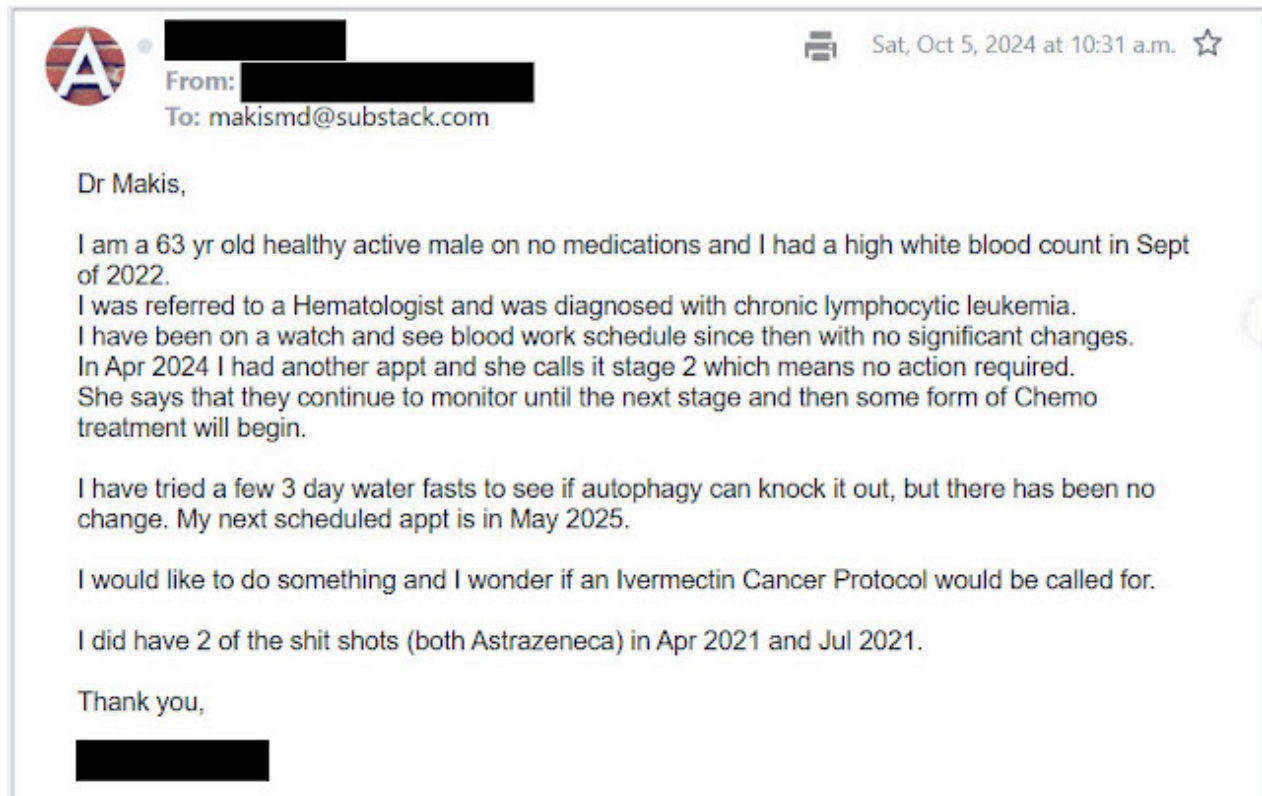
 **William Makis** Wed, Jan 15 at 8:58 p.m. ☆  
From: makisw79@yahoo.com  
To: [REDACTED]

Hi [REDACTED]  
is it my imagination or are your lymphocytes improving?

Re: Follow-up #348 - CLL Improvement - Lymphocytes 13 to 12.5 to 11.3 Yahoo/04 - TES... ☆

 Thu, Jan 16 at 5:02 a.m. ☆  
From: [REDACTED]  
To: William Makis

Dr.Makis,  
You're right! I was just looking at it being in the same range, but it is definitely trending down since beginning the protocol.  
Thank you,  
[REDACTED]



## 16. Lymphoma

### Case 4: December 2024 - Hodgkin's Lymphoma

Case testimonial from [PerilousPeg](#) (X/Twitter):

"Dr Makis, my daughter just beat Hodgkin's lymphoma with these drugs, supplements and a few other lifestyle changes. No chemo. No radiation. I have been telling people who are commenting on her video on TikTok with questions qbout ivermectin and [fenbendazole](#) to follow you."



### Case 3: December 2024 - Ivermectin and Fenbendazole for Large B-cell Lymphoma

Case testimonial from Dr William Makis ([X/Twitter](#)):

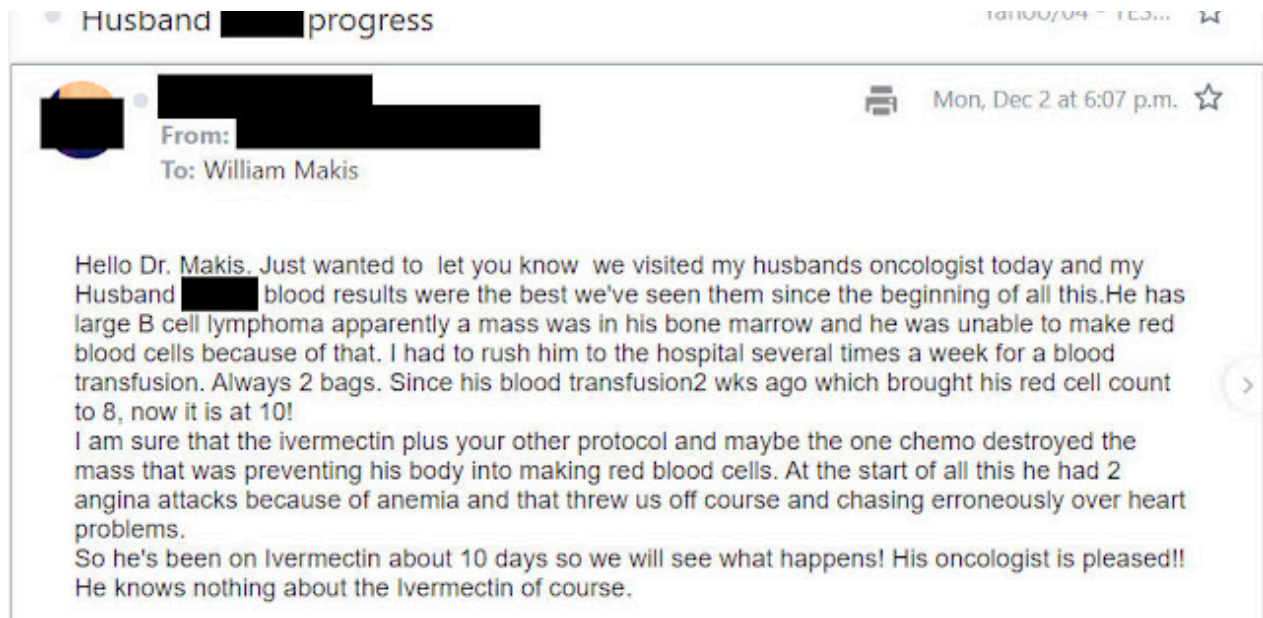
IVERMECTIN and FENBENDAZOLE Testimonial - 70s year old patient with Diffuse Large B-Cell Lymphoma - dramatic impact in first two weeks!!

70s year old USA patient recently diagnosed with LYMPHOMA.

We started a high dose Ivermectin and Fenbendazole Protocol

"We visited my husband's oncologist today and my Husband's blood results were the best we've seen them since the beginning of all this."

"He has large B cell lymphoma"



## Case 2: April, 2021

In 2020 my cancer returned, low grade lymphoma in the neck and chest. I refused to go on another course of chemotherapy and followed the **Fenbendazole** protocol instead. I decided not to inform the doctors on the protocol I will be using as they would argue that it is a crazy belief with no proof of success.

It is almost a year later today that I received my second biopsy and PET scan results coming back completely clear from any disease, meaning there were no signs of lymphoma found from the neck lymph node that was removed.

## Case 1: December, 2021

My twin sister was diagnosed with stage 2 non-Hodgkin's B-cell double hit lymphoma a few years ago, which is known to be a very aggressive cancer out there. She won the battle, but not so long ago found out that the lymphoma has returned.

As a family we had to weigh the options and see what the next best approach is to this fight against cancer and so her journey started on Fenben. Here is a list of the protocol and other supplements she used and still use today:

- **Fenbendazole** (222mg for the first few months and the increased the doses to 444mg/double)
- CBD

- Additional supplements (recommended by doctors in Mexico)

After she finished her second round of chemotherapy – the PET scan confirmed that she was cancer free, again, after being on the fenbendazole protocol along with the treatment she has been getting since. She still consumes fenbendazole as a preventative measure to ensure the cancer does not return ever again!

## 17. Melanoma

Please refer to Skin Cancer (chapter 26)

## 18. Multiple Myeloma

Case 1: January, 2022\*

\*Update January 2025:

These testimonials and those on the Heal Navigator website were actually taken from the Fenbendazole Cancer Support group and users of Happy Healing ( **The Happy Healing Store**) fenbendazole. These websites attribute success to Merck products which is absolutely incorrect. This testimonial was written by me yet credited to some other guy. This is my healing journey and I used Happy Healing products.

Who is William Scarf?

Multiple Myeloma

William Scarf

January, 2022

Condition: Multiple Myeloma

I was diagnosed with borderline active Multiple Myeloma about 5 years ago. As the symptoms got more they wanted to put me on chemotherapy but refused. I eventually got diagnosed with several other diseases like Lyme disease, Morgellons disease, RA, chronic skin conditions, Fibromyalgia, etc. I was in such pain. This is when I decided I had enough and got word of the fenbendazole protocol and decided to give it a go.

As time went by being on this course, I saw improvement with every trip to the doctor. I eventually became more functional and could start returning to my life after being under for a few years.

I then had to relocate due to work and it took me almost a year to find another oncologist to check my results. He was completely amazed after hearing my story and confirmed to me that I fully recovered from Multiple Myeloma. This is a miracle. I told the doctor that I have been using fenbendazole and even the doctor was astonished by my past results, stating that I am in a better condition than ever before!

The doctor still monitors me today on my fenbendazole usage which I take every day to ensure that my M-count does not spike. I am grateful and thankful to be pain free today. This is all thanks to fenbendazole.

Published as a January 2022 case testimonial on Heal Navigator:

"I was diagnosed with borderline active Multiple Myeloma about 5 years ago. As the symptoms got more they wanted to put me on chemotherapy but refused. I eventually got diagnosed with several other diseases like Lyme disease, Morgellons disease, RA, chronic skin conditions, Fibromyalgia, etc. I was in such pain. This is when I decided I had enough and got word of the **fenbendazole** protocol and decided to give it a go.

As time went by being on this course, I saw improvement with every trip to the doctor. I eventually became more functional and could start returning to my life after being under for a few years.

I fully recovered from Multiple Myeloma. This is a miracle. I told the doctor that I have been using **fenbendazole** and even the doctor was astonished by my past results, stating that I am in a better condition than ever before!

The doctor still monitors me today on my **fenbendazole** usage which I take every day to ensure that my M-count does not spike. I am grateful and thankful to be pain free today. This is all thanks to **fenbendazole**."

## 19. Myelodysplastic Syndrome

Dr William Makis shared on [X/Twitter](#) (January 2025):

**IVERMECTIN and FENBENDAZOLE Testimonial - 74 year old former Olympic athlete with Myelodysplastic Syndrome (MDS) post Moderna COVID-19 mRNA Vaccines - first improvement in blood counts in 2 years!**

Another short but inspiring story!

74 year old former Olympian had two Moderna COVID-19 mRNA Vaccines and recently developed **MDS (Myelodysplastic Syndrome)**.

From his wife:

*"I'm grateful I found you...he is on the Ivermectin and **Fenbendazole** regime I found on your site"*

After 1 month:

*"My husband had his blood tests last week and met with Oncologist today. For the first time in 2 years his blood counts are up and I can only attribute that to your Protocol of Ivermectin and **Fenbendazole** which he has been following for just a month"*

And now my favorite part 😊 *"You are a miracle worker and I think after the Rogan/Gibson podcast you will be very famous in the USA"*

Ok that was too sweet of her!

- 24mg Ivermectin (daily)
- 222mg Fenbendazole

These are relatively small doses but still effective!

I've had many requests to help patients with Myelodysplastic Syndrome (MDS) and the research is very limited but guess what...

several MDS patients and I are now working on it! 🙏

Many blood disorders respond to Ivermectin and Fenbendazole and this is a hot area of research for those of us staying one step ahead of mainstream oncologists and hematologists! 🤔

## 20. Oral Cancer

*Refer to Head and Neck Cancer (chapter 11).*

## 21. Ovarian Cancer: Fenbendazole, Mebendazole and Ivermectin

### Case 2: Dec 2024

According to Dr William Makis ([X/Twitter](#)):

IVERMECTIN & FENBEDAZOLE Testimonial - 40s year old Stage 4 Ovarian Cancer patient declared "CANCER FREE" after 2 months

40s year old Stage 4 Ovarian Cancer patient followed at a large US Cancer Centre (Mayo Clinic), reached out to me in July 2024

Patient was diagnosed in Feb.2024 with Stage 4 Ovarian Cancer (High Grade Serous Carcinoma)

She had 4 cycles of neoadjuvant chemo, then cytoreduction (surgery) June 24, then plan was for 2 additional cycles of chemo.

Post Surgery Cancer Clinic Visit in July 2024: plan was for 2 more chemo cycles - patient then

CA125 on July 15, 2024 peaked at 86.7 (pre-surgery it was 41.7)

Even though much of the tumor was removed, the CA125 had jumped from 41.7 to 86.7, indicating rapid cancer growth and spread

IVERMECTIN: We started a medium dose Protocol:

- Ivermectin 1mg/kg/day
- Fenbendazole 444mg/day
- Melatonin 100+mg/day

6th cycle of chemo


Two months later she was CANCER FREE.

Do you think the Chemo did it? The same chemo that after 4 cycles resulted in a CA125 of 41.7? And then rapid progression right after surgery? I don't think so.

It was the combination of chemo + IVERMECTIN Protocol.

Now, as of Dec.21, with a CA125 of 16 (in the normal range), she's been CANCER FREE since end of September.

Dr.Makis)

[Redacted] [Redacted]  Tue, Dec 17 at 10:49 a.m. ☆

**From:** [Redacted]  
**To:** William Makis

Good morning Dr. Makis,

I heard and see all the things are going on and I pray for your and your family protection.





I wanted to ask you when can I do follow up with you!  
[Redacted]

I will also donate too.  
PS. My last test was last week  
C 125 -16

I am still in your protocol .

Warmly: [Redacted]

Sent from my iPhone

← Back ↶ ↷ →  Archive  Move  Delete  Spam ... ▲ ▼ ✕

● Re: ZOOM LINK (Consultation with Dr.Makis) Yahoo/0 - DON... ☆

[Redacted] [Redacted]  Thu, Sep 26 at 3:16 p.m. ☆

**From:** [Redacted]  
**To:** William Makis

Hi Dr.Makis,

I hope life treats you well.  
I just wanted to let you know where I am.  
I finished last treatment.  
Had a blood work and CT and shoed C. Free.  
I have been on your protocol for 2 months.  
Before that I was taking Fen B half the dose for 4 months.

I am doing fasting but got only up to 20 hours.

Do you have any recommendations for me or should I keep staying on your protocol.  
Still struggling taking very high dose melatonin.  
I bought 10mg.  
So I take 50mg.

Thank you for your knowledge Dr. Makis!

Kindly: [Redacted]

Sat, Jul 27 at 11:34 a.m. ☆

From: [Redacted]  
To: makisw79@yahoo.com

Hi there,

My name is [Redacted]  
I greatly appreciate doctors like you , who authenticy want to help patients.  
I was diagnosed with ovarian cancer in February.  
I went trough 5 chemos amd a major surgery .  
Have one more chemo left.

I hav e been working on diet, supplements, nutrition etc.  
I would like to make an appointment tue first step to learn and know what is best thing next to do.

Thank you!  
Sincerely: [Redacted]  
Sent from my iPhone

Re: Cancer Consultation Yahoo/0 - DON... ☆

Sun, Aug 4 at 8:14 p.m. ☆

From: [Redacted]  
To: William Makis

Hello Dr. Makis,

Cancer diagnosis, Stage, treatments done and current status of disease:

High grade serous carcinoma  
Had 4 cycles of chemotherapy, full hysterectomy, spleen, appendix, and distal pancreas removed (6/24), followed by a 5th chemo, and last chemo will be next week (6 total chemotherapy)  
CA-125  
See most recent clinic note 'Scan0114' for history,  
COVID-19 Vaccine history: **none** (refuse to take any vaccines)

Date Collected: **07/15/2024**      Date Received: **07/15/2024**      Date Reported: **07/24/2024**      Fasting: **Yes**

**CA 125, Serum (Serial)**

Test	Current Result and Flag	Previous Result and Date	Units	Reference Interval
▲ <b>Cancer Antigen (CA) 125<sup>01</sup></b>	<b>86.7 High</b>	<b>41.7</b> 05/10/2024	U/mL	0.0-38.1
Roche Diagnostics Electrochemiluminescence Immunoassay (ECLIA) Values obtained with different assay methods or kits cannot be used interchangeably. Results cannot be interpreted as absolute evidence of the presence or absence of malignant disease.				


COVID INTEL

IVERMECTIN & FENBEDAZOLE Testimonial - 40s year old Mayo Clinic Stage 4 Ovarian Cancer patient declared "Cancer Free" after 2 months

DR. WILLIAM MAKIS MD  
DEC 21, 2024 · PAID

Send the gift of COVID Intel - by Dr. William Makis this holiday season [Send a gift](#)

3 1 Share



### Case 1: October 2024

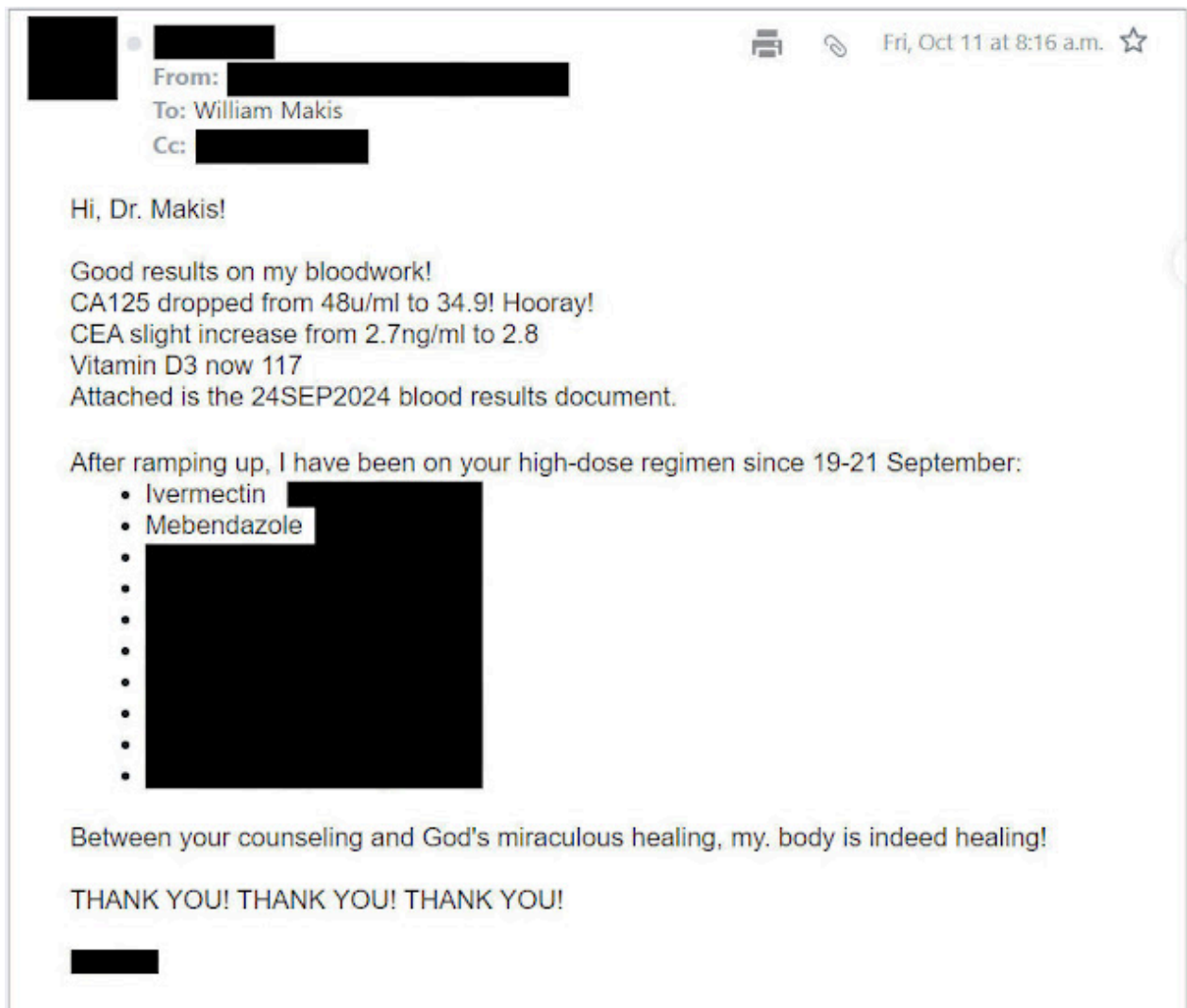According to Dr William Makis ([X/Twitter](#)):

*IVERMECTIN and MEBENDAZOLE Testimonial in a patient with Advanced Ovarian Cancer.*

*3 weeks of high dose regimen results in CA125 cancer marker drop of 30%!*

*Ovarian cancer is very responsive to Ivermectin but people forget about Mebendazole (FDA approved version of **Fenbendazole**). (Hint: combine them)*

*We hit this cancer hard and have it on the run 3 weeks in!*



Note: Although technically mebendazole is not the same as **fenbendazole**, both mebendazole and **fenbendazole** are part of a larger group of drugs known as benzimidazole\*, which are anthelmintic drugs (i.e., drugs that kill parasitic worms).

\*The class of drugs known as benzimidazoles includes **fenbendazole**, mebendazole, albendazole and flubendazole.

**Fenbendazole** and mebendazole are similar in that they both eliminate parasitic worms, but there is a difference. Mebendazole is approved for human consumption by the FDA, while **fenbendazole** is only approved for veterinary use and has not been approved for human use.

Mebendazole is the form that is approved for human use while **fenbendazole** is approved for veterinary use. The main difference is the cost. Mebendazole is expensive ~\$450 per pill (two pills of mebendazole cost just \$4 in the UK.), while **fenbendazole** is inexpensive ~48 cents per

While most of the pre-clinical research uses mebendazole, probably because it is the FDA-approved-for-humans form of **fenbendazole**, virtually most of the self-treating clinical reports involve the use of **fenbendazole**.

## 22. Pancreatic Cancer Success Stories

### Case 9

Dr George Fareed shared on [X/Twitter](#) (January 2025):

"Patient with stage 4 pancreatic cancer today txted: Great news. Tumor is much smaller than before. 5.4cm to 3.3 cm. I've gained about 12 lbs. He continued IVM/mebendazole protocol started 10/24 as well as chemo started 11/24."

### Case 8: December 2024

Case shared by Dr William Makis ([X/Twitter](#)):

IVERMECTIN and **FENBENDAZOLE** Testimonial - 40s year old man with Stage 4 Pancreatic Cancer post 2x Pfizer mRNA Vaccines, sees 91% drop in CA19-9 in 2 months!

Possible case of Turbo Cancer post 2 Pfizer COVID-19 mRNA Vaccines

40s year old man diagnosed with Pancreatic cancer in 2022 post 2 Pfizer COVID-19 mRNA Vaccines.

Had Whipple procedure, then 12 cycles of chemo and 2 months of radiation.

Treatments ended May 2023.

Recurrence in June 2024 (mass encasing SMA & liver lesions)

Restarted chemo in July 2024 but chemo wasn't working. CA19-9 was skyrocketing.

I was consulted in October 2024. We immediately started high dose Ivermectin (up to 2mg/kg/day) and high dose **Fenbendazole** (up to 888mg/day)

2 months later: (you can read the email for yourself)

91% drop in CA19-9 cancer blood markers! 28340 to 2699. This is my favorite part, seeing results like this, especially when chemo was failing.

It's worth persevering on high doses of Ivermectin, **Fenbendazole** or Mebendazole, and i know it isn't always easy. We struggle with this sometimes.

   
From:   
To: William Makis

Mon, Dec 2 at 6:12 p.m. ☆

Dr. William Makis,




Amazing news! My husband  has been taking Ivermectin and Febendazole since October 2024!  
His CA19-9 was 28430. Last Friday he had bloodwork and his CA19-9 is now 2699!!! This even with taking a small break from Ivermectin due to some Neuro symptoms and a little bit of visual disturbance...which has all resolved. A side from the side of effects of chemo he is doing pretty well. Can't wait to see how the scans look in the next couple of months.

Thank you for the work that you do. Annnnd for giving us a real chance. My little family is so grateful. Our sons have a real chance at a future with their Dad!!!  
Happy Holidays to you and your family. We hope  
You all are staying safe ❤️

With gratitude, 




• Stage 4 Pancreatic Ca UPDATE Yahoo/04 - TES... ☆

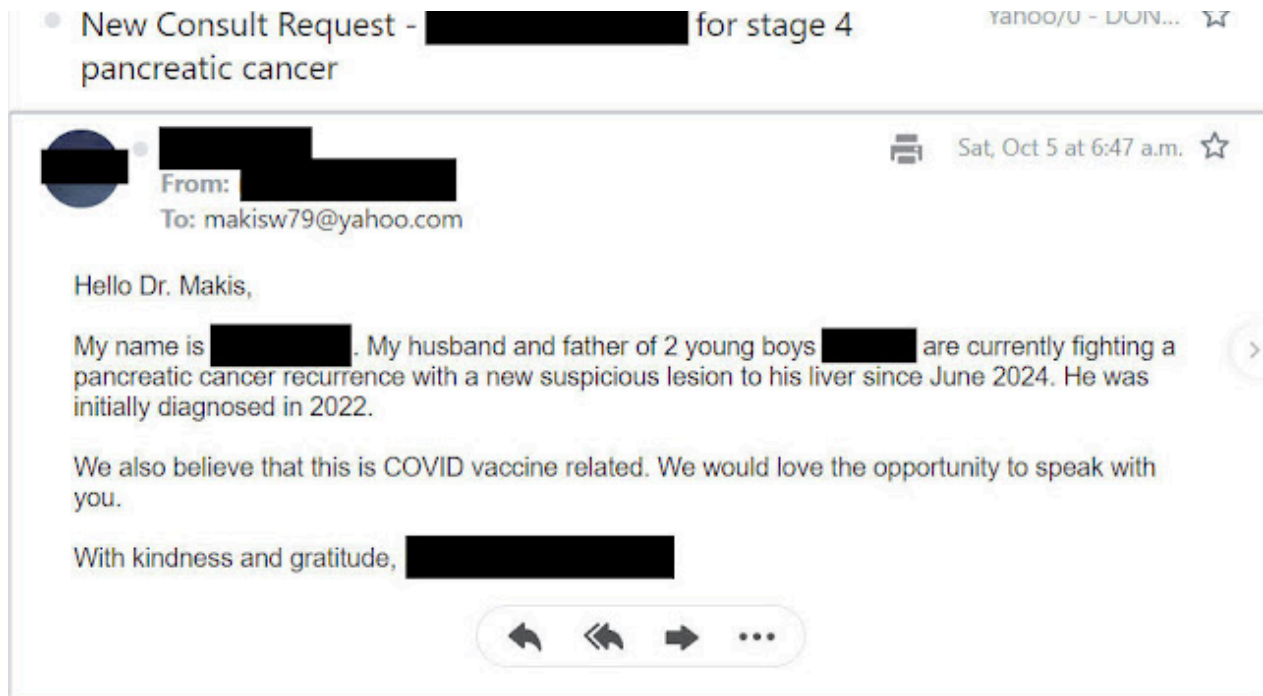
   
From:   
To: William Makis

Thu, Nov 7 at 4:22 p.m. ☆

Hi Dr. Makis,

My husband had his follow up labs and CT this past week. At the time  had been on Ivermectin and Feben for only 2 weeks. But the CT showed no further mets and the tumor in the pancreas had gotten smaller by 2 mm. I know this is a very small change...but the fact 5FU wasn't working yet there was no progression of disease proves to me that your protocol is working.

They have switched him to gemcitabine which according to my research is even more effective with Ivermectin.



### Case 7: November 2024 (Pancreatic Cancer)

Case shared by Dr William Makis (X/Twitter):

*IVERMECTIN and FENBENDAZOLE Testimonial - Pancreatic Cancer - CA19-9 drops 1349 to 450 in less than 2 months - loving daughter outsmarts Oncologist!*

*This is a Pancreatic Cancer patient who didn't respond to first line chemotherapy, the best chemo that the Oncologists had in their arsenal.*

*Lessons:*

*Oncologist with his best medical training and best medicine = Pancreatic tumor grows 4.1cm to 4.6cm and CA19-9 rises 880 to 1349*

*Loving daughter with internet and dog medicine = CA19-9 drops 1349 to 450.*

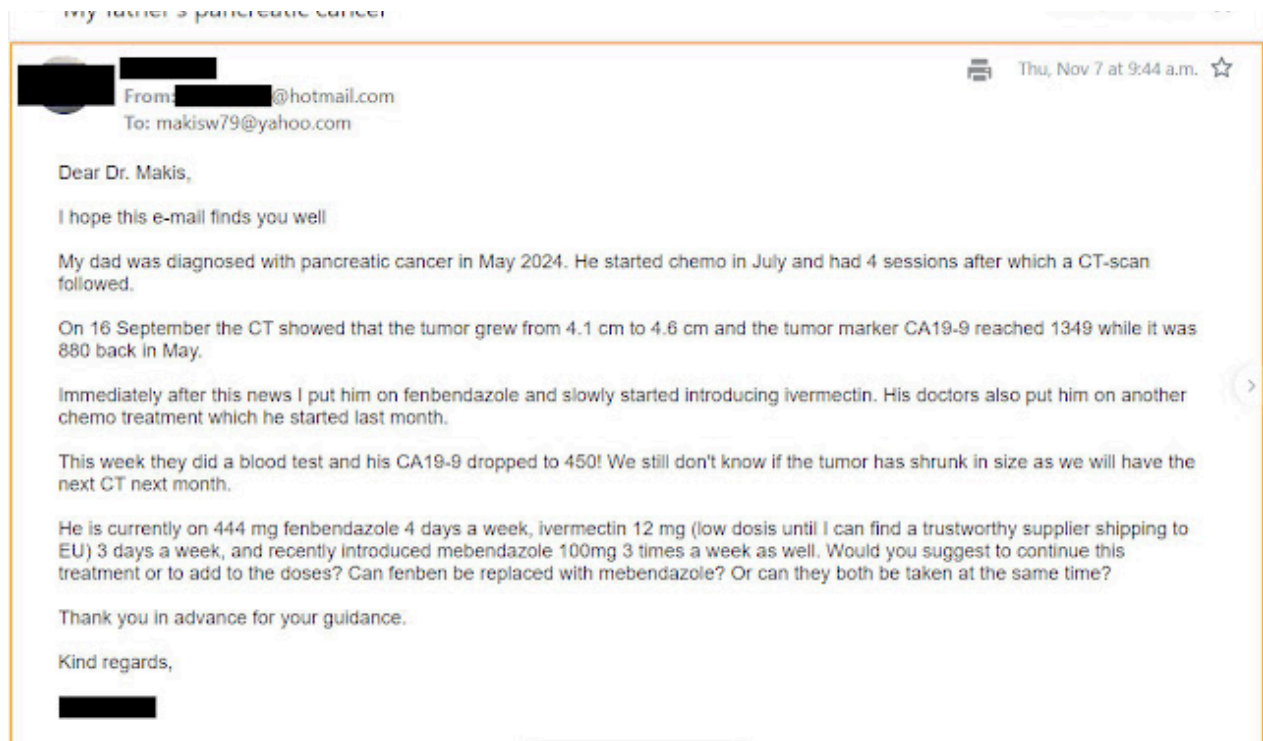
*Low doses can work:*

*12mg Ivermectin (I would have done 60mg)*

*444mg Fenbendazole 4/7*

*(I would have done 6/7 or even 888mg)*

*She still did brilliantly. Work with what you have and don't be afraid. The daughter outsmarted the best Oncologists with their best medicine!*



### Case 6: November 2024 (Stage 3 Pancreatic Cancer)

Case shared by Dr William Makis (X/Twitter):

*IVERMECTIN and FENBENDAZOLE Testimonial - 50s man with Stage 3 Pancreatic Cancer - incredible response to therapy after 8 weeks - 75% drop in CA19-9*

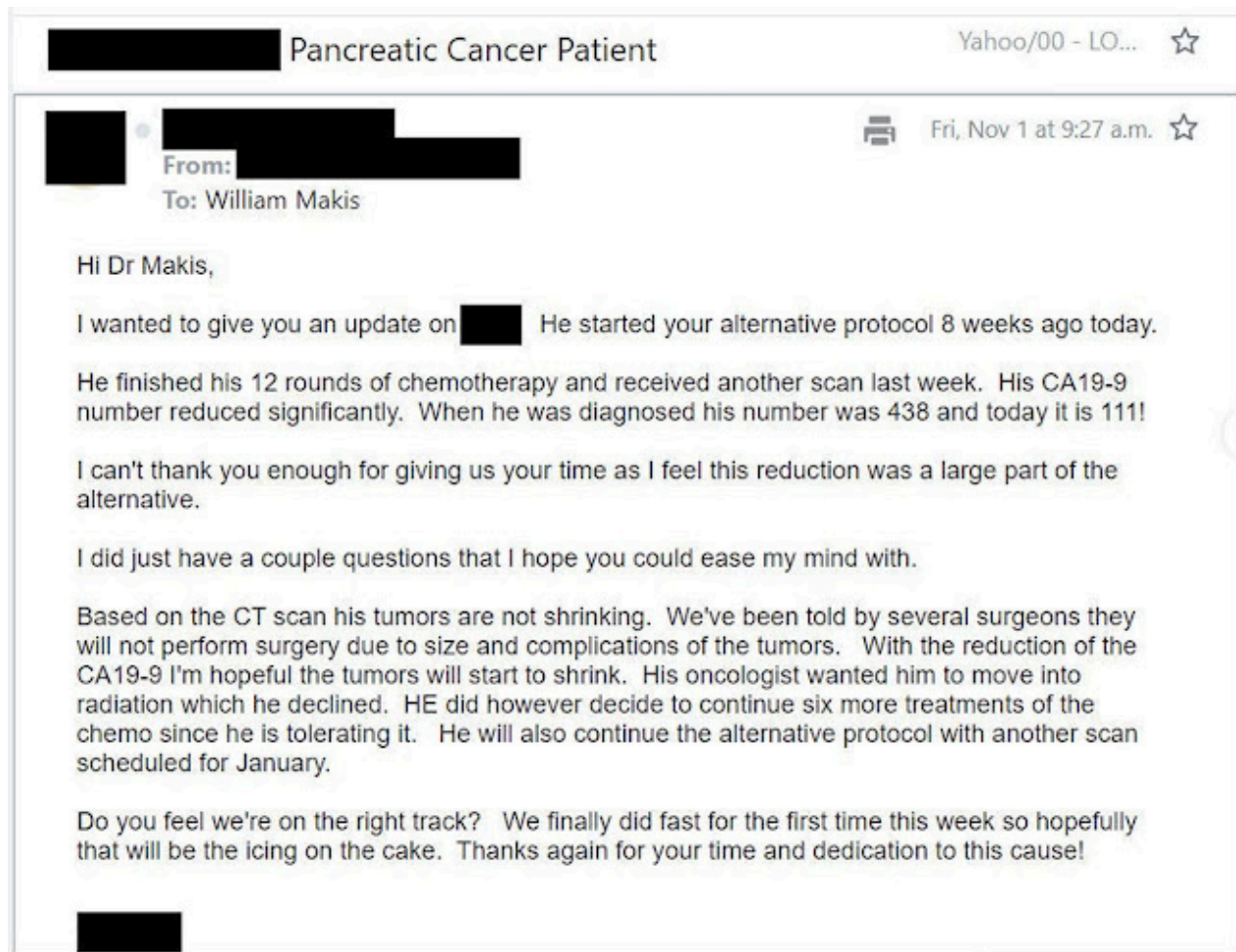
*75% reduction in blood tumor marker CA19-9 after only 8 weeks of high dose Ivermectin and Fenbendazole is wild! We're certainly on the right track.*

*75% of cancer cells may be dead, no longer producing tumor markers. Excellent question and lesson point here. Is it problematic that the tumor is not shrinking yet?*

*That takes a bit longer and is a more involved process. That's why a PET/CT scan would be good here. We could see the metabolic activity of the tumor drop dramatically, suggesting most of the cancer cells are dead, even if the tumor mass hasn't shrunk yet.*

*Some Oncologists are good at ordering them, some aren't.*

*It takes time for the body to re-absorb or clear dead tumor cells from a solid mass. The tumor mass could be 75% dead cells and still appear unchanged in size. Eventually the body does get to*



### Case 5: October 2024 (Stage 4 pancreatic cancer)

Posted by [Dave on X.com](#):

*My dad is still alive today 2.5 years after a terminal stage 4 pancreatic cancer diagnosis thanks to MEBENDAZOLE. His pancreatic tumor has been undetectable for 2 years.*

**Note:** Although technically mebendazole is not the same as **fenbendazole**, both mebendazole and **fenbendazole** are part of a larger group of drugs known as benzimidazole\*, which are anthelmintic drugs (i.e., drugs that kill parasitic worms).

*\*The class of drugs known as benzimidazoles includes **fenbendazole**, mebendazole, albendazole and flubendazole.*

**Fenbendazole** and mebendazole are similar in that they both eliminate parasitic worms, but there is a difference. Mebendazole is approved for human consumption by the FDA, while

Mebendazole is the form that is approved for human use while **fenbendazole** is approved for veterinary use. The main difference is the cost. While most of the pre-clinical research uses mebendazole, probably because it is the FDA-approved-for-humans form of **fenbendazole**, virtually most of the self-treating clinical reports involve the use of **fenbendazole**.

#### Case 4: September 2024 (Last update)

William Makis MD reposted

 **Mama's Mead & Menageries**  @FranDHexe · 10h

Replying to @MakisMD

I did an ivermectin/fenbendazole combo to help with my recurring pancreatic tumor! This stuff works! I love seeing all these success stories!

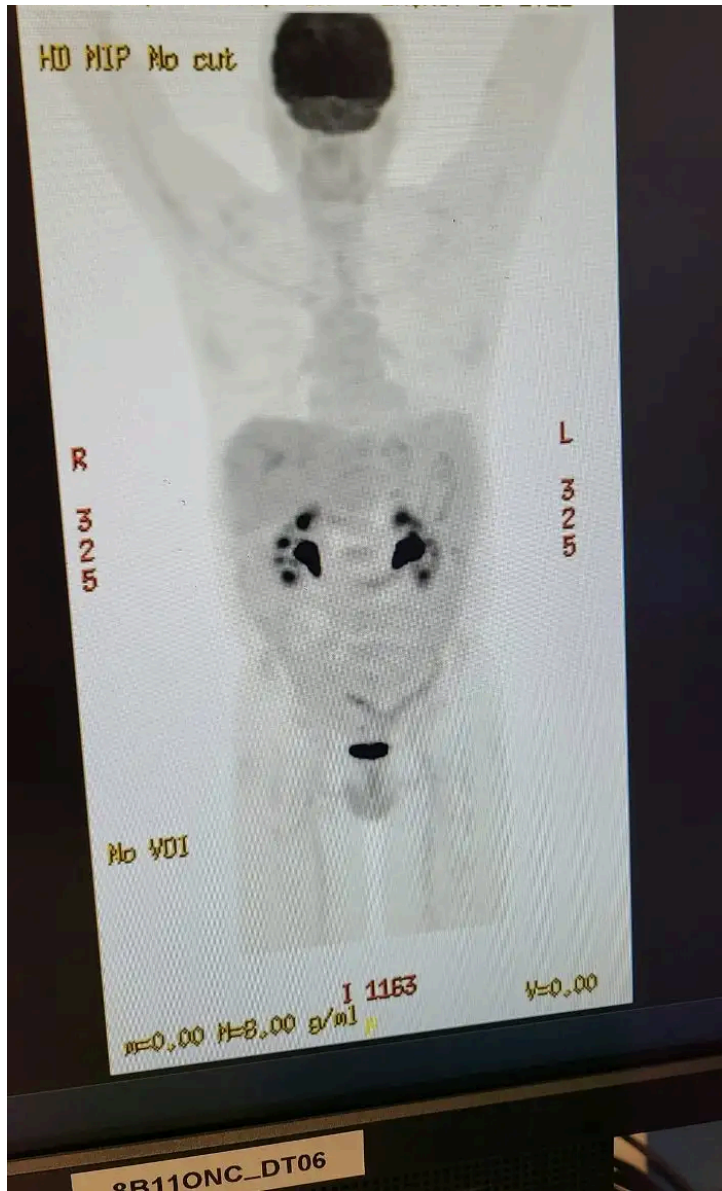9 23 174 6.2K

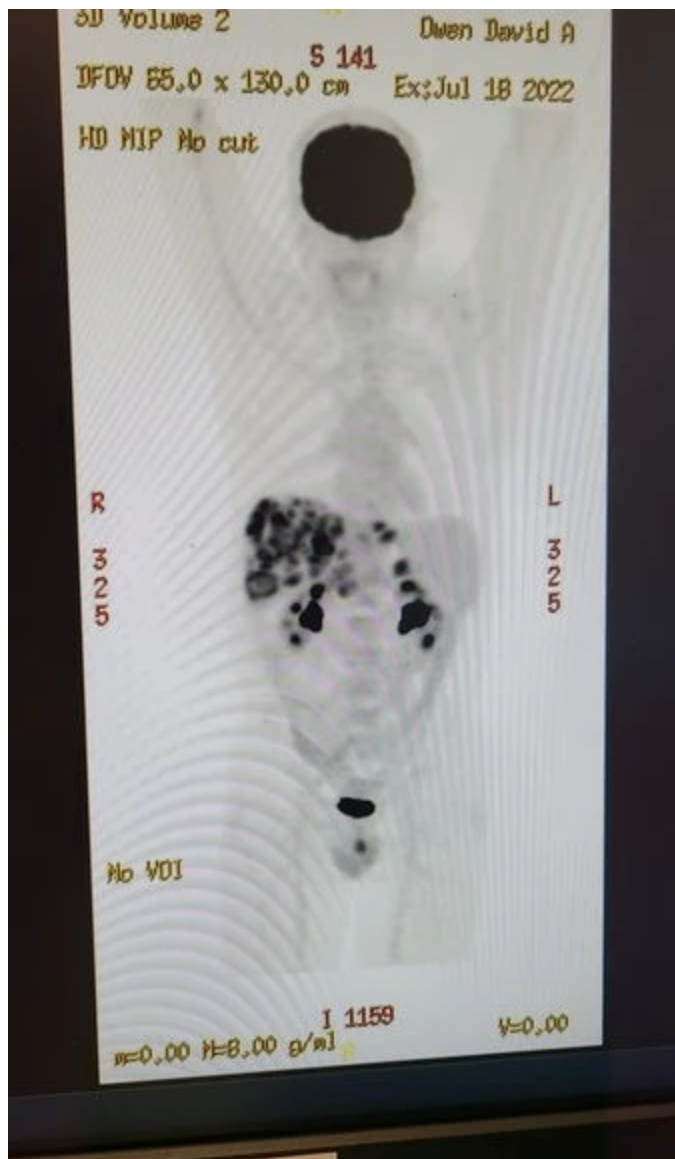
Source: [X/Twitter](#)

#### Case 3: December, 2022

I'm in Remission!! Pancan stage 4 to liver. 5 months JTP 4 months of that 5 with Chemo biweekly. Check out my scan images.(The black areas on 2nd image are my kidneys). I'm getting last chemo infusion today then going on maintenance pills. God Bless Joe Tippens, God, all the prayer warriors. Never give up yall !!

Your welcome to share my story anywhere and everywhere. I feel I was saved so that I can be a testament to the protocol and share it as much as I can.





### Case 1: June 2024

“My Cancer Story! I was diagnosed with stage 4 pancreatic cancer in August 2023, and without treatment, I had 3-6 months to sort out my affairs.

I began my **fenbendazole** protocol immediately.

I nearly quit up since my quality of life had deteriorated dramatically. But I started to feel better. Less nausea. I had gained some weight back! Increased energy. My scan in November 2023 indicated that this severe cancer had neither grown or spread. My cancer marker dropped from over 100,000 to 35,000. As of January 2024, my new marker number was 18k!!! My oncologist was just scratching his head, and a family member said he seemed bewildered! And no, I did

I was terrified he'd drop me as a patient. I was quite appreciative for fenben and how it has helped me. I was feeling better and stronger. I had scans and bloodwork done in March, and my markers are now down to 6000. And the tumors were shrinking!!! Two weeks after my previous scan. I scanned again, and it returned NED.

I was diagnosed with stage 4 pancreatic cancer in August 2023, and without treatment, I had 3-6 months to sort out my affairs. I began my fenbendazole Protocol immediately. I nearly quit up since my quality of life had deteriorated dramatically. But I started to feel better. Less nausea. I had gained some weight back! Increased energy. My scan in November 2023 indicated that this severe cancer had neither grown or spread. My cancer marker dropped from over 100,000 to 35,000. As of January 2024, my new marker number was 18k!!! My oncologist was just scratching his head, and a family member said he seemed bewildered! And no, I did not inform him about the fenben.

I was terrified he'd drop me as a patient. I was quite appreciative for fenben and how it has helped me. I was feeling better and stronger. I had scans and bloodwork done in March, and my markers are now down to 6000. And the tumors were shrinking!!! Two weeks after my previous scan. I scanned again, and it returned NED.

This was my protocol:

## •MORNING

- Curcumin (600mg daily)
- Zinc (50mg)
- Milk thistle, As a food supplement, take 15 - 30 drops, 2-3 times daily in a little fruit juice or water. 7 days a week
- Serrapeptase (120,000iu)
- Fenbendazole (1000mg of Panacur C is advised to be taken seven days a week. It is recommended that it should be taken with a meal).

## •NIGHT

- Curcumin (600mg tablet per day are recommended
- Berberine (600mg 2-3 times a day )
- Quercetin (500mg 1/day)
- Turkey Tail
- Vitamin E (800mg for 7 days a week)
- Fenbendazole (1000mg at night)
- Ivermectin 12mg daily 5/7days a week
- Limit sugar and processed food intake
- Drank green tea often

Morning

- **Milk thistle**, As a food supplement, take 15 – 30 drops, 2-3 times daily in a little fruit juice or water. 7 days a week
- **Serrapeptase (120,00IU)**
- **Fenbendazole (1000mg** of Panacur C is advised to be taken seven days a week. It is recommended that it should be taken with a meal).

Night

- **Curcumin (600mg tablet per day are recommended**
- **Berberine (600mg 2-3 times a day )**
- **Quercetin (500mg 1/day)**
- **Turkey Tail**
- **Vitamin E (800mg for 7 days a week)**
- **Fenbendazole (1000mg at night)**
- Ivermectin 12mg daily 5/7days a week
- Limit sugar and processed food intake
- Drank green tea often”

The original source of this article is [COVID Intel](#).

### Case 2: March, 2023

My family member was diagnosed in stage 4 pancreatic cancer in August 2022. She was told it was very aggressive and without treatment she had 3-6 months and to get her affairs in order. She started 220 fenben immediately. She was very ill and hospitalized with sepsis and colitis from eating tainted peanut butter. She lost about 20 pounds. It took 2 months to start chemo, which made her very sick. We almost gave up because her quality of life had declined significantly. But she started feeling better. Less nausea. She has gained weight back! More energy.. Her latest scan showed this aggressive cancer has not grown or spread. Her cancer numbers or markers went from being over 100k down to 35k.

\*\*\* UPDATE: As of today, march 2nd, her new marker number is 18k!!) Her oncologist was just scratching his head.. my family member stated he looked confused! And no, she didn't tell him about the fenben. We are afraid he would drop her as a patient. We are so very grateful for fenben and how it's helped her. She is feeling better, stronger, and enjoying her family. I have never posted on here. But I wanted to give you some hope!

\*\*UPDATE\*\*She had scans and bloodwork done 2 weeks ago and we got the results today!! She is eating better and gaining weight.. Her markers are now down to 6000. AND THE

## 23. Prostate Cancer Success Stories

Case 11 - 16: February 2025

The screenshot shows a Substack post titled "IVERMECTIN and FENBENDAZOLE - Six short but incredible Prostate Cancer Testimonials!" by Dr. William Makis MD, dated Feb 04, 2025. Below the post is a tweet from Larson HSV (@bluecitycrime) dated Feb 2, 2025, with 44K views. The tweet text reads: "Stage 4 prostate fighter/survivor. On Iver and FenBen for 19 months. Cancer undetectable for the past 12 months. I told my Oncologist of my protocol, and he told me 'we don't have parasites. This isn't a third world country.' No chemo. Pray to the Lord. Start this protocol".

Cases shared by Dr William Makis (X/Twitter):

Case 01:

*78 year old man with Prostate Cancer Gleason 9 post prostatectomy, halted recurrence with "your low dose protocol"*

*"So there you have it. My PSA has stopped rising, still 1.2 and my annual scan and MRI in December were still clear after 3 months on the low dose protocol"*

Case 02:

Case 03:

Brig Gen (Ret) USAF:

*"my prostate cancer was eradicated using IVM, Fenben and Doxy"*

Case 04:

*"I have more positive results to report!"*

*"My husband got his PSA results back today. When he was diagnosed with prostate cancer his PSA was 5.8 now it is down to 4.1 after 32 days on Ivermectin and*

**Fenbendazole"**

Case 05:

*"I was told by one local oncologist that I had 2 months to 2 years max"*

*"This past summer moved to high dose Ivermectin and I feel a huge improvement. I take 48-60mg daily and that had the affect of depressing my PSA significantly. But again, the real measure is I feel so much better"*

Case 06:

*"Praise the Lord for Dr.Makis and his wisdom, kind compassionate heart and generosity!! Wonderful start to a Happy New Year!"*

*"My husband has recently been diagnosed with Prostate Cancer.*

*We started:*

*Daily IVM 96mg*

*3x/week fenben 888mg*

*LDN*

*Orgovyx*

*PSA 538 (12/6/24) down to 290 (12/30/24)*

*"God Bless you and your beautiful family Dr.Makis!"*

**Case 10: December 2024**

Case shared by Dr William Makis ([X/Twitter](#)):

**IVERMECTIN and FENBENDAZOLE Testimonial - 79 year old Canadian man with Stage 4 Prostate Cancer to Lymph nodes - everything is shrinking 4 months later!**

79 year old British Columbia, Canada man diagnosed with Prostate Cancer, Gleason 8, "pushing against bladder wall, in lymph nodes, diagnosed late 2022 with a PSA peaking at 19.72.

Completed 28 treatments of radiation.

Was currently on hormone blockers (and Abiraterone) but tumor hasn't shrunk.

**Came to me for help and we got to work right away:**

We started the following protocol:




- Ivermectin 1mg/kg/day
- Fenbendazole 444mg/day
- Melatonin 120mg/day
- IP6
- Artemisia

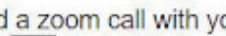




**RESULTS:**

"approaching 4 months on Ivermectin plus the other products"



**"the oncologist report is that there is shrinkage in all areas (prostate, bladder wall and lymph nodes. He is not in remission as yet".**

The answer to the question is: continue Protocol until remission.

  Sun, Dec 22 at 4:56 p.m. ☆  
**From:**   
**To:** William Makis


We had a zoom call with you on November 4 th. (  and our son  .  started high dose age of Ivermectin on September 8 th, plus a few weeks later, he added the Fenben and the supplement protocol that you recommend. So  is approaching 4 months on Ivermectin plus the other products.


He had a scan at the end of November.....the oncologist report is that there is shrinkage in all areas. ( prostate, bladder wall and lymph nodes). He is not in remission as yet.

My question is: Should  continue on with the high dose ivermectin plus fenben? If so, for how long? Thank you very much! We really appreciate everything you are doing to help people, Dr Makis. 

Sent from my iPad

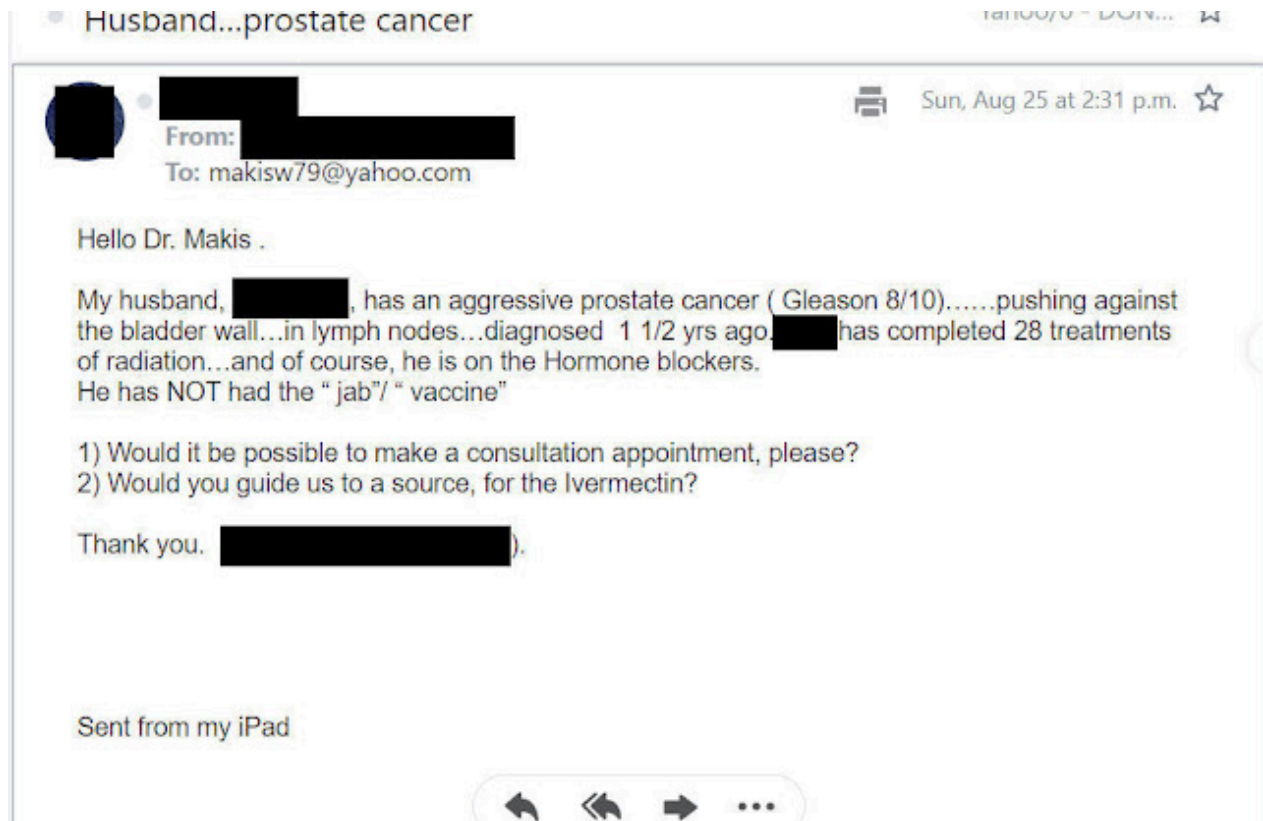• Re: Husband...prostate cancer Yahoo/0 - DON... ☆

  Wed, Aug 28 at 7:54 a.m. ☆  
**From:**   
**To:** William Makis

P.s. Re:   
's most recent cat scan ( last month) showed that the tumour hasn't shrunk...but his PSA continues to go down. He exercises 6 days a week and his attitude is very good. 

Sent from my iPad

On Aug 28, 2024, at 12:52 AM, William Makis <makisw79@yahoo.com> wrote:



### Case 9: December 2024

Case shared by Dr William Makis ([X/Twitter](#)):

IVERMECTIN and FENBENDAZOLE Testimonial - 60s year old Early Stage Prostate Cancer patient, Gleason 7, PSA drop 4.6 to 2.46 in 35 days!

60s year old Prostate Cancer patient, new diagnosis, Gleason 7 (3+4 and 4+3) with bilateral disease.

Major US Cancer Center gave this assessment:

*"Overall, I think you will eventually come to need treatment of your prostate and because you appear to have bilateral disease, whole gland treatment is likely the best cancer strategy. Whether undergoing treatment now, or observing for a bit longer is the best route depends on your goals. We can consider radical prostatectomy...I'm less enthusiastic about radiation treatment as you are very young and likely to experience the secondary effects of radiation on your normal tissue as you age."*

Patient did about a month of Fenbendazole 222mg Joe Tippens Protocol, then I got involved.

We started a high dose Ivermectin/Fenbendazole Protocol: 1mg/kg/day Ivermectin working up to 2mg/kg/day 888mg/day Fenbendazole.

Results one month later:

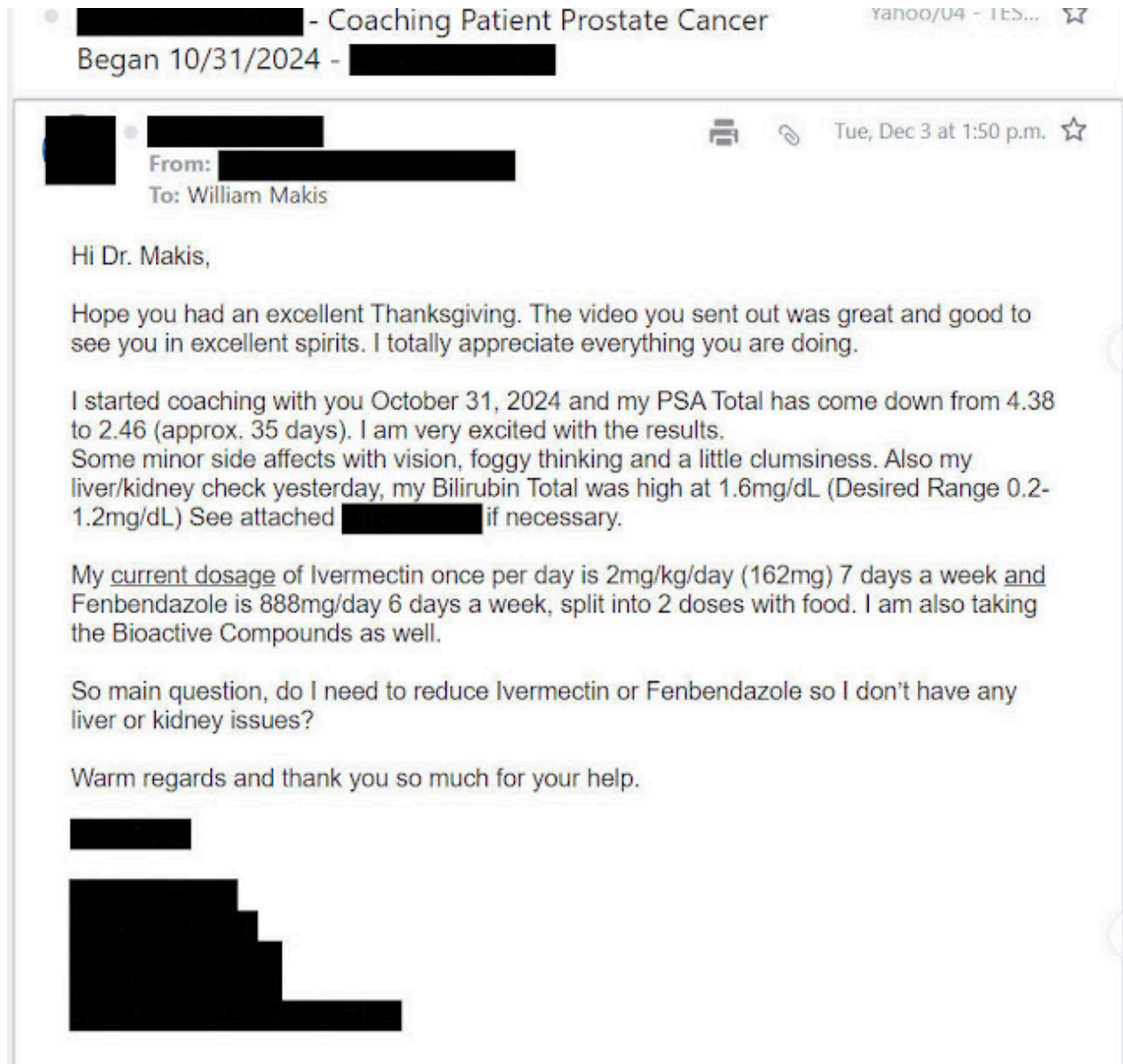PSA went: 4.4 to 3.6 to 2.46 (lowest PSA level in 2 years!) 44% drop in PSA in about one month!

Transient visual symptoms affect some patients at Ivermectin doses above 60mg. They tend to go away with time.

Why the high dose Ivermectin/Fenbendazole regimen?

- young patient
- "A Gleason Score of 4+3 represents a moderately aggressive form of prostate cancer."
- "bilateral disease at the prostate apex plus an additional region with cancer at the base."

I find that Ivermectin and Fenbendazole are well tolerated and it's very rare to see any issues on bloodwork.



### Case 8: November 2024

Case sharing by Dr William Makis ([X/Twitter](#)):

IVERMECTIN and FENBENDAZOLE Testimonial - Stage 4 Prostate Cancer patient - PSA drops 1533 to 968 in 12 days - is fatigue and bone pain normal?

Stage 4 Prostate Cancer patient:

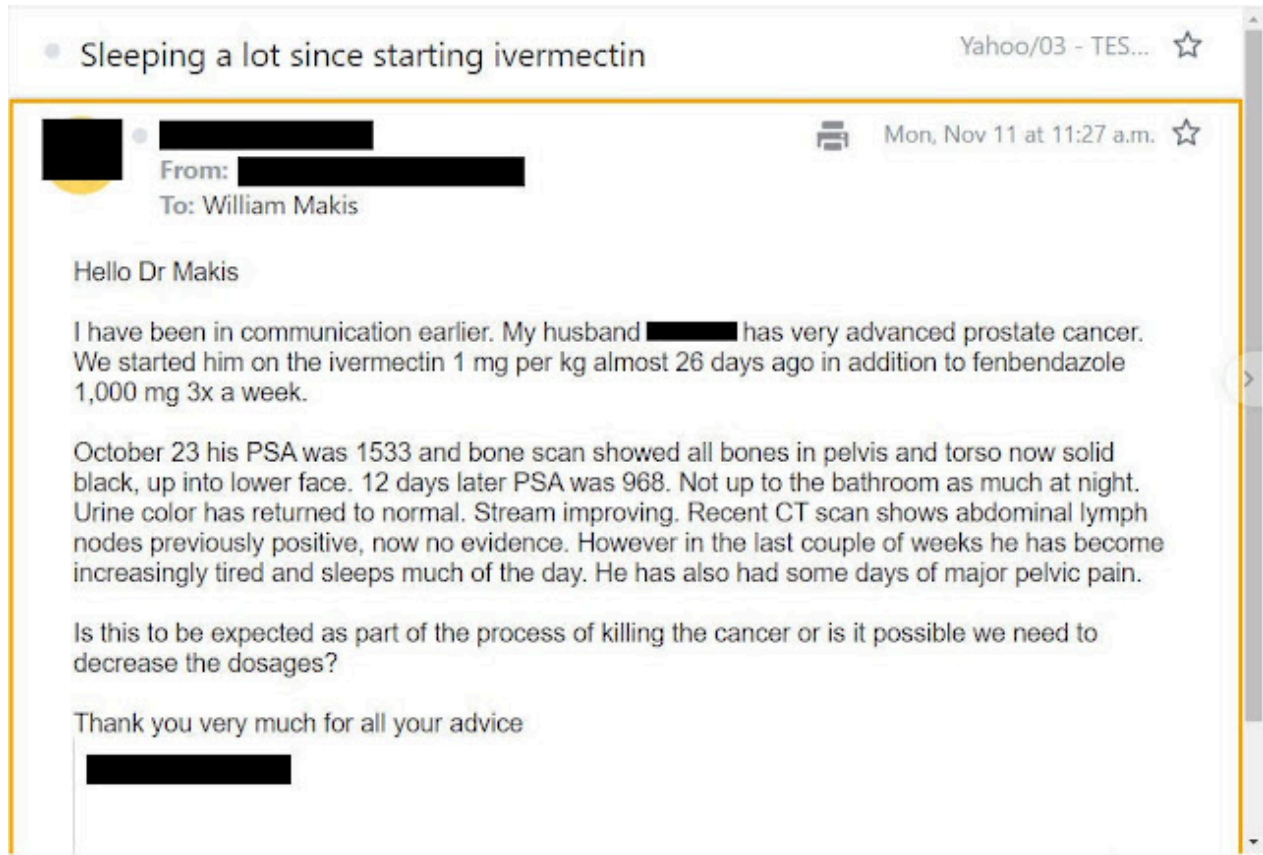
Started Ivermectin 1mg/kg and Fenbendazole 1000mg 3 days on 4 days off.

In 12 days PSA drops 1533 to 968 (37% drop). Abdominal cancer lymph nodes disappeared.

That will cause a great deal of FATIGUE. That's to be expected.

Bone pain? Also. As cancer cells in bone get killed, the inflammation can also cause bone pain. That will heal over time

This gentleman is on his way to becoming cancer free.



## Case 7: November 2024

Case sharing by Dr William Makis ([X/Twitter](#)):

IVERMECTIN and FENBENDAZOLE Testimonial - Stage 4 Prostate Cancer patient from Ecuador, Gleason 8, goes on Protocol and PSA drops from 800 to 18 in 3 months!

Patients from around the world (hello Ecuador!) are benefiting from Ivermectin and Fenbendazole repurposed drug combination Protocols.

This was an Intermediate Dose Protocol, with a starting dose of Ivermectin of 1mg/kg/day and a Fenbendazole dose of 222mg to 444mg a day.

Re: Prostate cancer Yahoo/Inbox ☆

   
From: @hotmail.com  
To: William Makis Thu, Nov 7 at 7:56 a.m. ☆

Hello Dr. Makis,

I consider it is importante to tell you briefly how is the situation with my husband, he has been receiving biomagnetism therapy and doing a cetogenic diet and since May his PSA was in 800 now has decrease to 18 (his last exam was yesterday). So considering this new PSA we want to know if he has to take the same dose you send him at the beginning?  
I think your treatment should be the next step to cure him because his PSA is a little stuck and does not decrease so fast like the beginning.

Dose you send us:  
1mg/kg/day of Ivermectin  
222mg or 444mg of Fenbendazole

Thank you for everything.

On Aug 9, 2024 11:30 AM, William Makis <makisw79@yahoo.com> wrote:

Hi 

1mg/kg/day of Ivermectin  
222mg or 444mg of Fenbendazole, depending on what he can handle

William

On Thursday, August 8, 2024, 11:31:31 p.m. MDT,   
@hotmail.com> wrote:

Hello doctor Makis, I'm writing you in desperate need, my husband is suffering from prostate cancer adenocarcinoma acinate 4+4=8 Gleason. Is about to start his quimio treatment, but I want to know what dosis should I give him of ivermectin and if he have to take also fenbendazole?  
We are from Ecuador that's why I don't attach you all of his medical exams cause they are in Spanish.

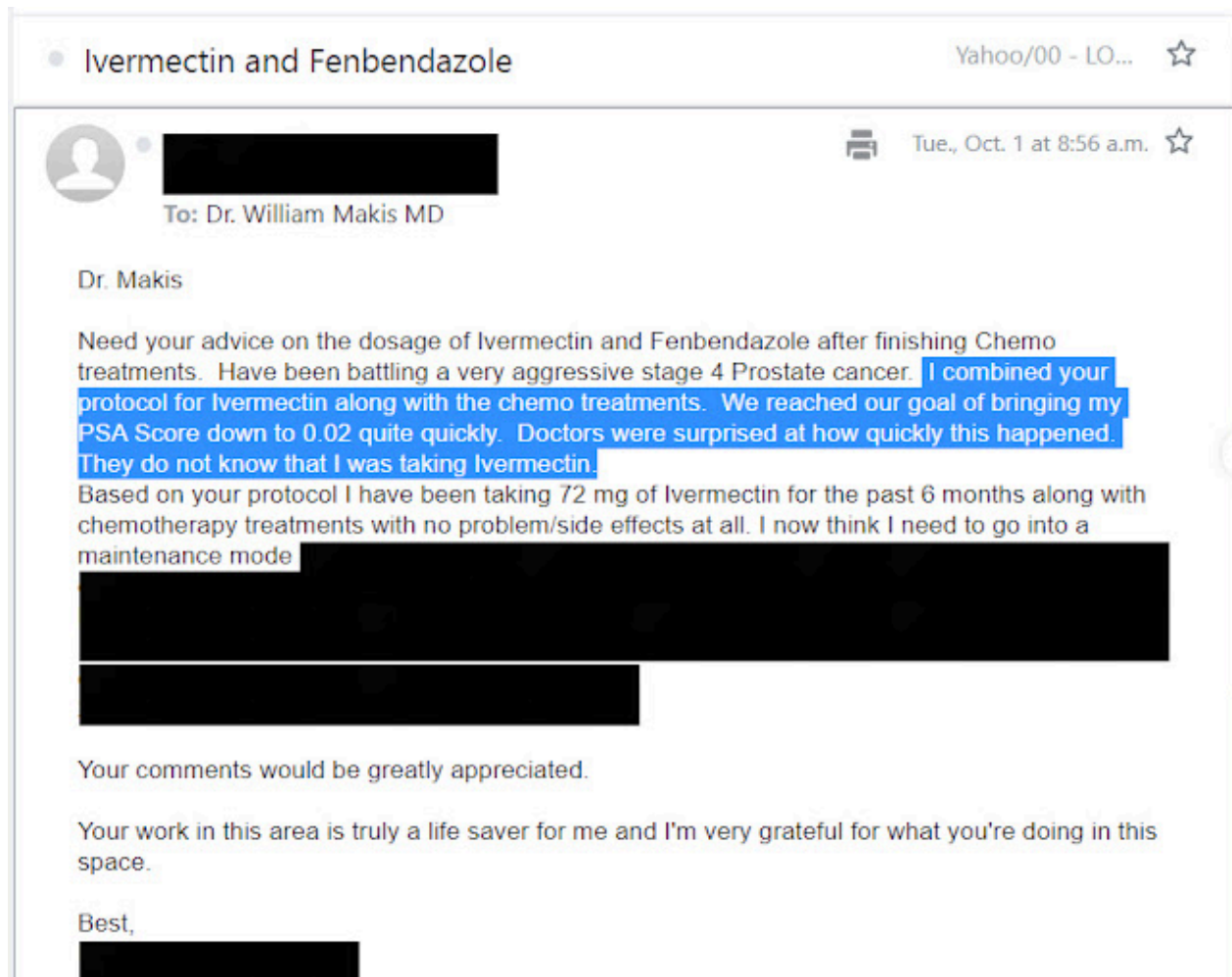
Thank you for your kindly help

Regards,  


### Case 6: October 2024

According to Dr William Makis (X/Twitter):

"We reached our goal of bringing my PSA Score down to 0.02 quite quickly. Doctors were surprised at how quickly this happened."



### Case 5: December 2022 (Updated August 2023)

I wish to share more good news. Since our texts, December 2022/January 2023, my husband has had two more PSA tests. Here is the recap of his tests . Lenny's PSA continues to drop, as he continues to take the Panacur C daily.

#### Lanny – PSA Test Results

8.0 = Lanny's PSA upon being diagnosed with prostate cancer, August 2021 Before Lanny 'started' radiation therapy, he had THREE WHOLE MONTHS of Panacur C daily. Lanny's doctor said any PSA under 1.0 is considered CANCER-FREE.

Lanny told his doctor about taking Panacur C, when the doctor told Lanny that his PSA was 0.8 (according to that very doctor, this PSA denotes cancer-free; however, this same doctor gaffed off the Panacur C and cancer-free PSA with NO explanation).

0.09 = Lanny's 30-DAY POST RADIATION PSA TEST, WHICH DENOTES WAAAY CANCER-FREE, February 2022 Still no comment from any doctor . . . and I'm not anticipating one.

PSA Updates: 0.08 = February 2023

0.06 = June 2023

December 2022

Lanny was diagnosed with prostate cancer August 2021.

8.0 = Lanny's PSA upon being diagnosed with prostate cancer.

Lanny's doctor said any PSA under 1.0 is considered CANCER-FREE.

Before Lanny started radiation therapy, he had THREE MONTHS of Panacur C daily.

0.8 = Lanny's PSA after 3 months of Panacur C – BEFORE radiation therapy.

Lanny told his doctor about taking Panacur C, when the doctor told Lanny that his PSA was 0.8 (which, according to that very doctor, this PSA denotes cancer-free; however, his doctor gaffed off the Panacur C and cancer-free PSA with NO explanation).


0.09 = Lanny's 30-DAY POST RADIATION PSA TEST, WHICH DENOTES WAAAY CANCER-FREE.

Still no comment from any doctor and I'm not expecting any.

BTW, Lanny made a personal decision to continue using Panacur C as cancers are notorious for returning.



#### Case 4

 Patricia Beaupre Mar 11 ❤️ Liked by 2nd Smartest Guy in the World

Same for my brother who is 80. He takes both Ivermectin and Fenbendazole with positive results. When I first mentioned it to him he was skeptical but I kept sending him the success stories and he finally decided to take it. His latest blood draw saw a big drop in his prostate numbers. His doctor was puzzled as it had been going up previously. I'm thankful he decided to try it and also very thankful for these articles. Thank you 2nd Smartest Guy!

❤️ LIKED (4) 💬 REPLY (1) 📤 SHARE

source: <https://substack.com/home/post/p-155091883>

#### Case 3: September , 2022

My husband was diagnosed 8 months ago.. Feb 1st of this year,, with a aggressive form of prostate cancer that had already metastasized into his lymph nodes and bones. He had fractures throughout his spine, ribs and pelvis. Adams bone scan showed cancer in his bones from his skull,, facial bones, clavicle, sternum right rib cage and most of his spine and pelvis.. His oncologist (we've since changed) waited 7 weeks to start any hormone therapy or chemotherapy and told us radiation wasn't even an option. Only 6 rounds of doxi. He sat at our first office visit Feb 2nd and told my family that the #1 man in our lives would be gone within 18 months. His psa was 140, Gleason score of 9. He was diagnosed full blown stage 4-5

before.. this was our time.. We had always talked about IF cancer ever came about for either of us we would research alternative treatments. We fear medical poison as much as the cancer itself..

Thank God my husband's cousin connected us with a angel that gave us all the information we needed on a product meant for animals, **fenbendazole** and even sent us 2 bottles of **fenbendazole**. Has since supplied us with bottles when needed.

So week 2 post diagnosis Adam started his 222mg of fenben.

### Case 2: March, 2022

I received the awful news two years ago from my Urologist that I have prostate cancer. The doctor wanted to prepare me for surgery immediately, but I refused to go for surgery. I was very afraid and gave up hope at some point till I discovered the **fenbendazole** protocol. Thanks to reaching out to a couple of people who have been on the course before and after sharing their stories with me I decided to take the protocol on with full commitment.

### Case 1: June, 2022

After having two scans and a biopsy and being told that I have stage 1 prostate cancer .I was told by a friend about **Fenbendazole**. After taking it for a year I had another M.R.I. and biopsy and the cancer is gone. Like a miracle.

Used: **Fenbendazole** , Vitamin E

## 24. Salivary Gland Cancer

### Case 1 (January 2025)

Shared on a [Facebook Private Group](#) (January 2025):

"I was diagnosed with stage 4 salivary gland cancer in April 2023. Had surgery and got most removed then did a very light chemo and 30 rounds of radiation. In August of 2023 my scans came back clean. We thought I was all done! Around March I had follow up scans done and now I have tumors on my spine, tailbone, liver, lung and pelvis. I've been on the **ivermectin**, **fenbendazole** protocol for a few months now. I'm from Kansas city and they aren't really familiar with my type of cancer...it's pretty rare. We came to MD ANDERSON Sunday to see if there is more they can do for me. I had scans done today but no results as of yet. The doctor

grace of God, my Lord and Savior will help prolong my life cause I'm definitely not ready to go yet! Thank you for letting me share....God bless all of you"

## 25. Sarcoma (Bone Cancer)

### Case 2: IVERMECTIN & FENBENDAZOLE for Stage 4 Spindle Cell Sarcoma

Dr William Makis shared on X/Twitter (November 2024):

IVERMECTIN & FENBENDAZOLE Testimonial - 70 year old woman with Stage 4 Spindle Cell Sarcoma gets 60% tumor shrinkage & multiple metastases disappear with low dose protocol  
70 year old woman with Stage 4 Spindle Cell Sarcoma originally in the right leg, with lung metastases.

She took the following:

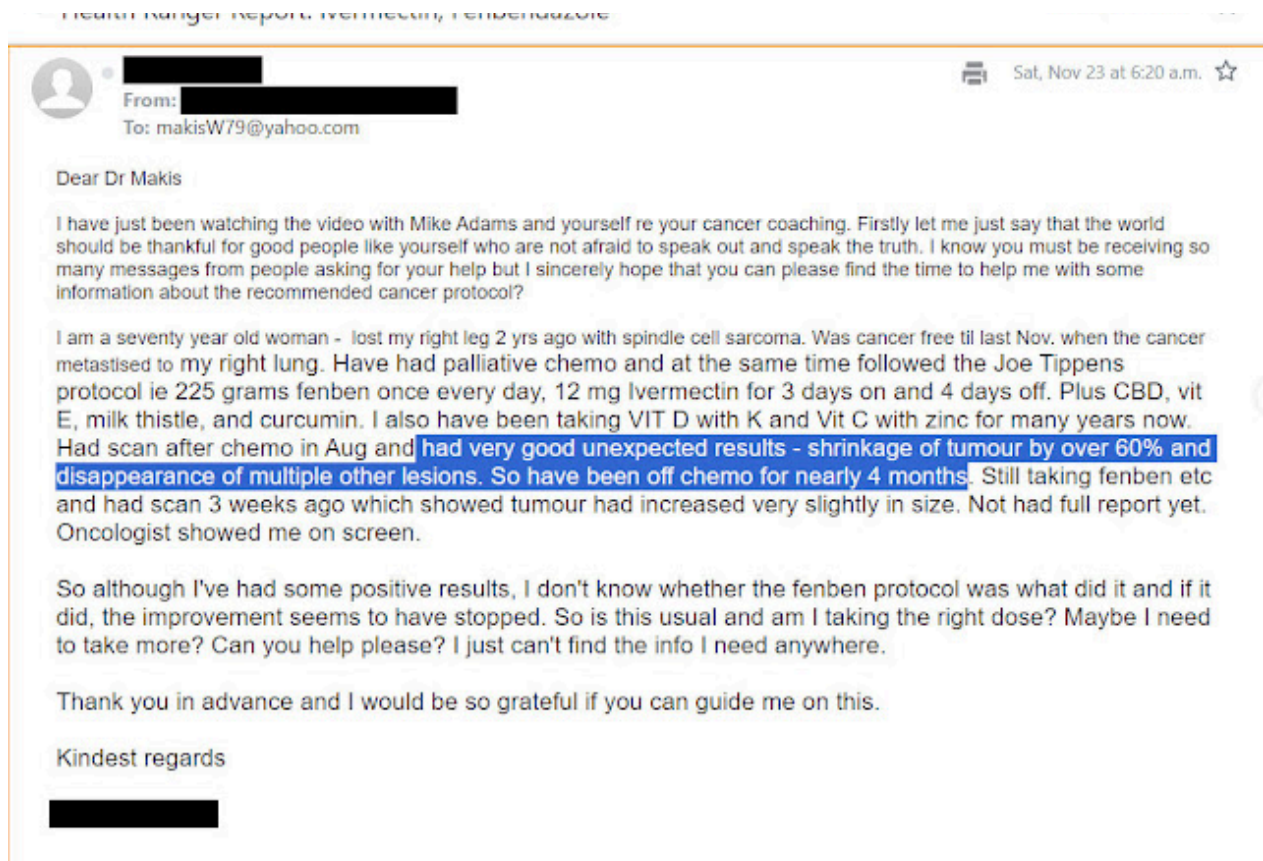
Palliative chemo (was not expected to help and it's all the doctors had left to offer)

222mg Fenbendazole 3 days on / 4 days off (Joe Tippens Protocol)  
12mg Ivermectin 3 days on / 4 days off

Unexpected Results: tumor shrinkage by 60% & disappearance of multiple lesions (!!)

My Take... Spindle Cell Sarcoma is a cancer that's notoriously difficult to treat. The response rate of chemo is on the order of 20% (which means 80% of patients don't see ANY improvement). The ones who respond see minimal results. To get tumor shrinkage by 60% and disappearance of multiple lesions is stunning. The chemo was palliative and was not expected to help in this case.

So yes, it wasn't the chemo. Sorry. And these were VERY LOW doses of Ivermectin & Fenbendazole !! I tend to suggest higher doses as cancer killing with Ivermectin & Fenbendazole is dose dependent.



The response rate to chemotherapy for soft tissue sarcoma, including spindle cell sarcoma, varies by study and treatment: [🔗](#)

- **Doxorubicin:** The response rate for doxorubicin monotherapy is around 20%. [🔗](#)
- **Doxorubicin and ifosfamide:** The objective response rate for doxorubicin and ifosfamide is around 20–30%. [🔗](#)
- **Doxorubicin and trabectedin:** When combined, doxorubicin and trabectedin can shrink tumors enough to allow for surgical removal in 20% of patients. [🔗](#)
- **Talimogene laherparepvec and pembrolizumab:** In a phase 2 trial, the best overall objective response rate was 35%. [🔗](#)

### Case 1: September, 2023

Condition: Alveolar Rhabdomyosarcoma (Bone and Muscle cancer)

When my 13 year old son was diagnosed, I basically became a cancer researcher! I discovered a few new very promising treatments that are close to being ready for pediatric use, and I also came across Joe Tippen's story. I joined a couple of large, international

the group whose 2 year old has the same type of cancer as my son, which had spread to his lymph nodes during frontline chemotherapy treatment. She started him on Fenben and his next 2 scans so far have been clear!

I would do anything to help my son beat the odds, and I came to the conclusion that it would be far more dangerous NOT to give him repurposed meds than to give them.

My husband supported my decision, but wanted some medical oversight, which we have received from Heal Navigator.

We noticed an improvement in our son's energy level and general health after just 2 days of giving him the Fenben! He had zero side effects, besides feeling a lot better.

I hope and pray that is a sign that it's doing what we need it to! If you're hesitating about getting started, I would encourage you to go for it!

Protocol components used: **Fenbendazole**, Curcumin, Milk thistle, Ivermectin, Vitamin D3, Claritin, Melatonin, Propranolol, Niclosamide, Mushroom blend, Omega 3, Papaya Leaf Extract as needed to raise blood counts.

Conventional treatments: Radiation, Chemotherapy

## 26. Skin Cancer and **Fenbendazole** (8 cases)

### Case 8: Stage 4 melanoma with mets to lymph nodes

Shared by [DavidCarl \(X/Twitter\)](#):

"As I've told you, my wife had stage 4 melanoma with mets to lymph nodes. She started taking ivermectin before you released your protocols, 1mg/kg. Weeks later you published your protocols and I bumped her to 2mg/kg. I added 444 mg of **fenbendazole**. Her last pet scan was approximately 6 months where she was cancer free. Her oncologist was all smiles, but I never told him I was giving her the protocol. She continues to take .5mg/kg of ivermectin 6x week and 3x week of 444 mg **fenbendazole**. She was taking immunotherapy for about a year before I read about ivermectin. Her lesions were having moderate response to the immunotherapy per pet scans. After putting her on ivermectin, 45 days later with a pet scan she presented cancer free. We were blown away. I almost cried. Doctor this is the hope you've given us. Your stories continue to give my wife confidence. It is like a big dark cloud we lived with was lifted."

### Case 7: Stage 3B Melanoma with liver failure

IVERMECTIN, **FENBENDAZOLE** and MEBENDAZOLE Testimonial:

FROM THE BRINK OF DEATH - Stage 4 Melanoma patient with extensive liver metastases given 2-3 days to live! Survives and most metastases are gone!

If you only read 1 of my testimonials EVER, make it this one.

Canadian patient had Stage 3B Melanoma 5 years prior. In Dec.2024, he presented to emergency in liver failure.

"He was told (by an Oncologist) Dec.2nd that he had 2-3 days to live and was in liver failure as his entire liver was consumed with tumors".

(Diagnosis: Stage 4 Melanoma recurrence with extensive liver metastases & liver failure)

"The only thing he (Oncologist) could suggest to try was Braftovi and Mektovi but has never given it to anyone with their liver in such bad shape – we are told that it is completely taken over with both cystic and solid lesions. Against our belief we were faced with a 'try or die...."

"He was given 1-2% chance with Braftovi/Mektovi so started that Dec.3rd"

"I reached out to you shortly thereafter and started your protocol. The CT results from Jan.30th (2025) that I am sending you show significant regression or complete resolution!!!"

Braftovi/Mektovi - 59 days

Ivermectin - 43 days

Mebendazole - 38 days

Fenben - 28 days

MAKIS IVERMECTIN CLINIC PROTOCOL Implemented:

Ivermectin 1mg/kg/day (43 days)

Mebendazole 400mg/day (38 days)

**Fenbendazole** 444mg/day (28 days)

Yes, you read that correctly. This is what's called "weighing the risks and benefits".

"All previously detected hepatic lesions have markedly regressed or resolved." "Excellent response to the interval instituted treatment regime, where there has been marked regression of the metastatic liver disease with associated significant reduction in the associated hepatomegaly. "There has been significant regression of the metastatic lymphadenopathy of the root of the small bowel mesentery" "there has been complete resolution of the underlying anasarca and ascites" "There are presently no signs of acute intra-abdominal/pelvic process observed"

----- My Take...

Do you know what is probably the single most frustrating question I get every day?

"Is Fenbendazole safe? My doctor told me it will damage my liver!" "My doctor told me Fenbendazole will destroy my liver"

Let me summarize:

Stage 4 Melanoma patient with extensive liver metastases told he had 2-3 days left to live... in LIVER FAILURE...

Implemented a Protocol with Ivermectin, Fenbendazole and Mebendazole!

And is alive 2 months later with all metastases either shrunk or gone! FROM THE BRINK OF DEATH... If anyone ever tells you that Fenbendazole or Mebendazole will damage your liver, know that they are lying to you, and if you want to, show them this story!

**Report**

**Adrenal glands:** The adrenal glands bilaterally appear unremarkable, without nodules or significant hyperplastic changes.

**Liver:** Redemonstrated is metastatic liver disease. Since the previous CT scan study, all hepatic lesions have undergone significant regression or complete resolution. For example, one of the dominant lesions seen on the previous CT scan study localized to the posterior segment of the right lobe of the liver presently measures 5.1 x 3.5 cm (axial image 50 series 616), whereas previously this lesion had measured 8.1 x 6.0 cm and therefore has significantly regressed. All previously detected hepatic lesions have markedly regressed or resolved. Associated with this significant regressing metastatic liver disease has been an overall significant decrease in the hepatic enlargement, where the liver is presently mildly enlarged, where the liver in the midclavicular line presently measures 19.3 cm in length. Associated with the regressing liver metastatic disease is significant reduction in the mass effect/compression upon the portal and hepatic venous segments, where they do not appear to be as attenuated as compared to the previous study. No evidence of interval developing portal or hepatic venous thrombosis. Associated with a regressing metastatic liver disease is a significant reduction upon the regional mass effect upon the adjacent organs of the upper abdomen, where the upper abdominal organs no longer appear to be displaced or compressed.

**Computed Tomography****Report**

interval regression. The previously seen largest lymph node at this site had measured 3.9 x 3.8 cm, whereas presently measures 2.2 x 2.1 cm (axial image 94 series 616). The other adjoining enlarged mesenteric lymph nodes have illustrated complete regression. No new developing mesenteric lymphadenopathy is observed. No signs of inguinal lymphadenopathy. Surgical clips in the left inguinal region are again noted from prior biopsy.

**Summary:**

There has been excellent response to the interval instituted treatment regime, where there has been marked regression of the metastatic liver disease with associated significant reduction in the associated hepatomegaly. In addition, there has been significant regression of the metastatic lymphadenopathy of the root of the small bowel mesentery. There has been complete resolution of the underlying anasarca and ascites.

There are no new interval developing manifestations of metastatic disease.

There are presently no signs of acute intra-abdominal/pelvic process observed.



From: [REDACTED]  
To: William Makis

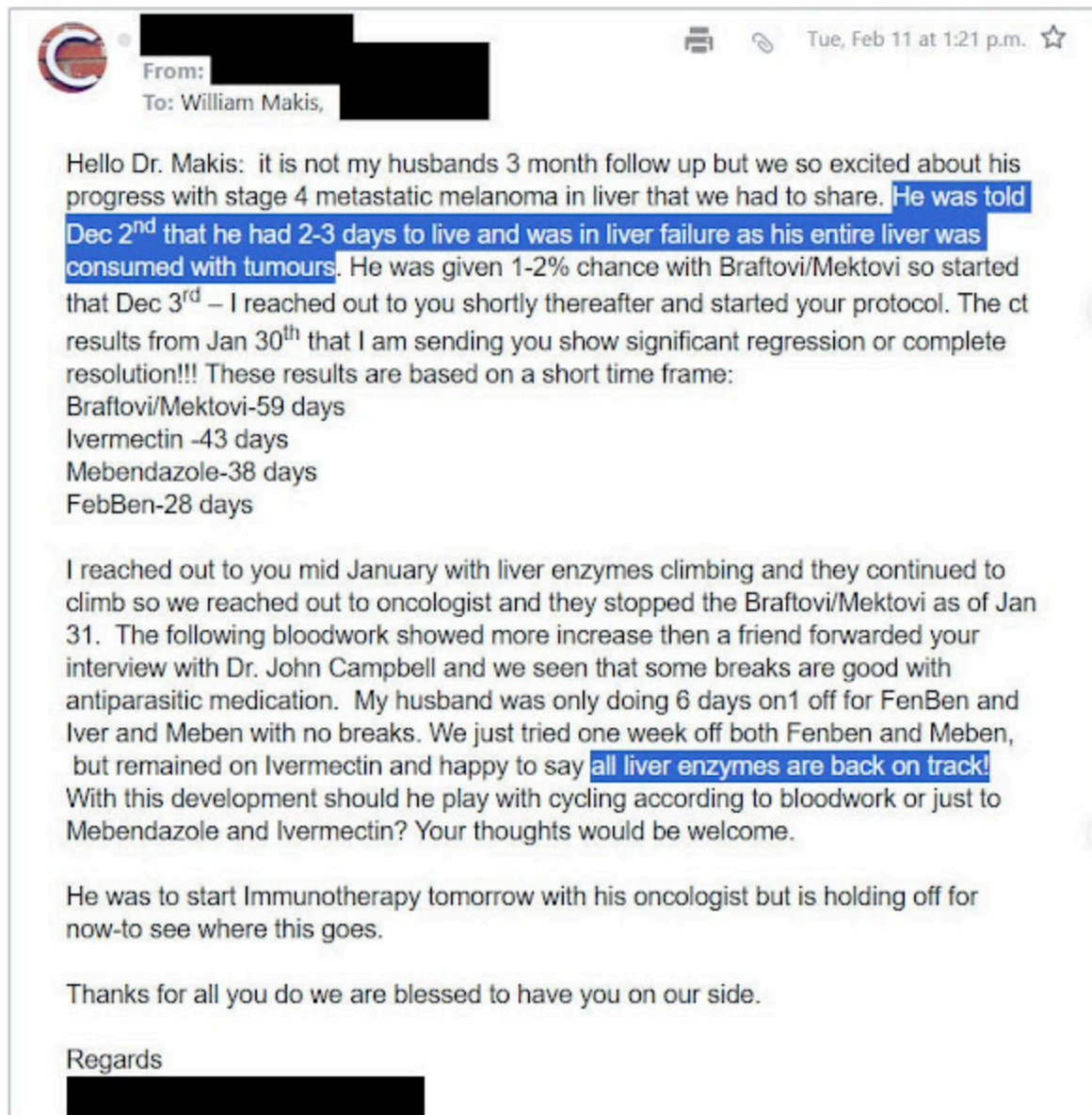


Sat, Feb 15 at 5:51 a.m. ☆

Hi Dr Makis: thank you for your reply. My husband was taking 1mg/kg Ivermectin, so 72 mg. Mebendazole 400 split in two -7 days on. febendazole 444mg/day split in two-6 days on 1 off.

As mentioned in previous email he has been on a break with Feben and Meben (Iver only) since last Tues/Wed (10 days) but was planning on restarting today. Liver enzymes came down considerably during the break (not normal but much less scary).

Feb 14.	Feb3. (Before break)
ALP 320.	410
ALT 104.	291
AST 46.	136
LD 218.	315
Billirubin 16.	20

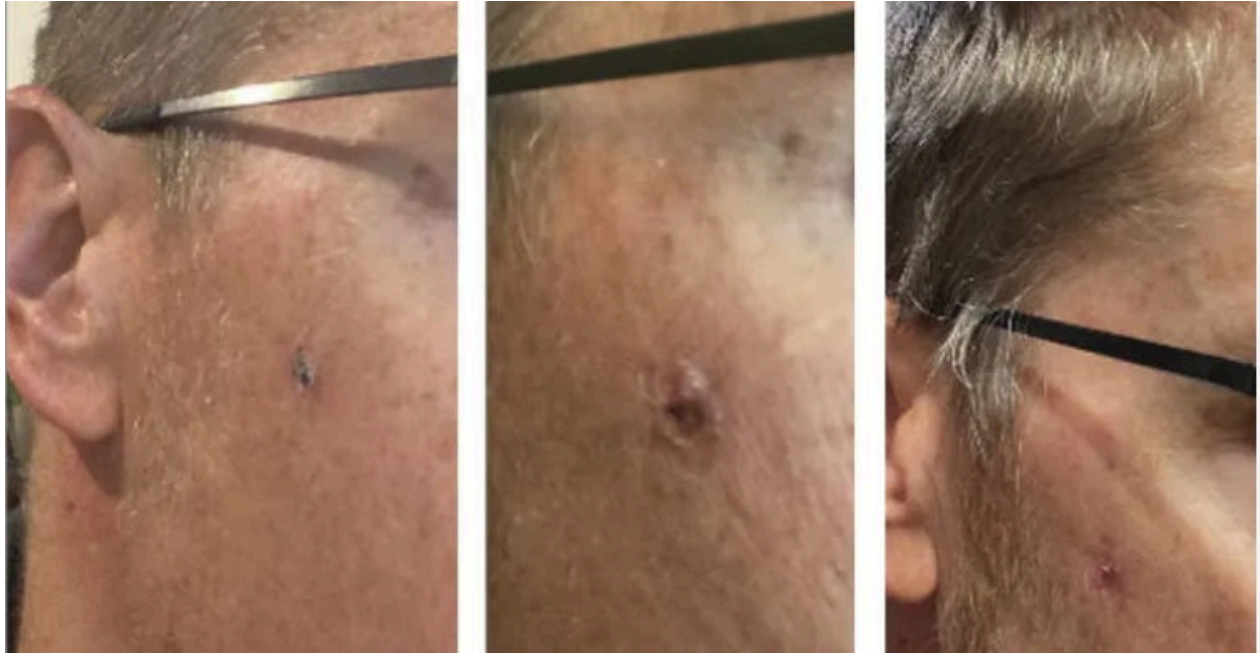

### Case 6: Basal Cell Carcinoma (BCC)

In this [December 2024 case report](#) published by Canadian Oncologist Dr. William Makis, we note the pictorial resolution of basal cell cancer [BCC] to the point that the patient may have to cancel his appointment for a planned surgical removal. One cannot surgically remove a basal cell cancer [BCC] that no longer exists.

This gentleman reports he is a long-time reader of Dr. Makis and was particularly interested in his reports of [Fenbendazole](#) and Ivermectin. He contracted basal cell cancer on his face in February or March of 2024, and did what most of us would do - he booked an appointment with his GP in June 2024, apparently the first available.

Having nothing to lose, he decided to apply **Fenbendazole** paste per the articles he had previously read, and to his pleasant surprise the persistent non-healing skin cancer of seven months began to shrink in size.

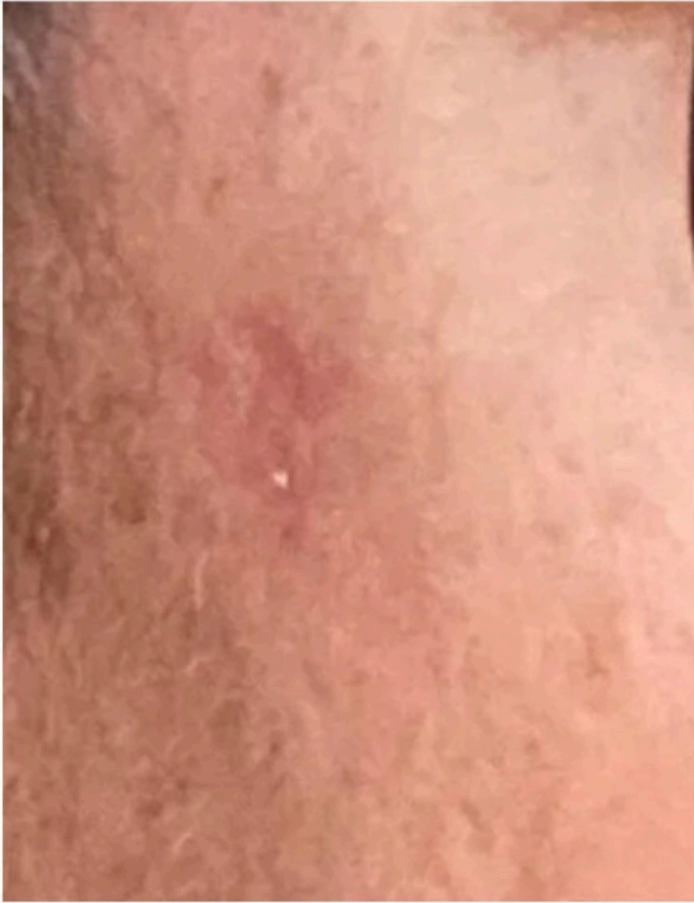

FenBen Treatment from September 25 through October 28, 2024

By the time of his November Dermatology appointment, there was very little to biopsy, yet it was done. He reports the Dermatologist was not the least bit interested in his tumor shrinkage with the **Fenbendazole** paste. Instead, the Dermatologist booked him for a tumor removal appointment three months later in February 2025.

The patient continued to apply the paste for the next month following the November biopsy, and here is what the BCC looked like as of December 6, 2024.

off after the biopsy, and this is how it looks now:



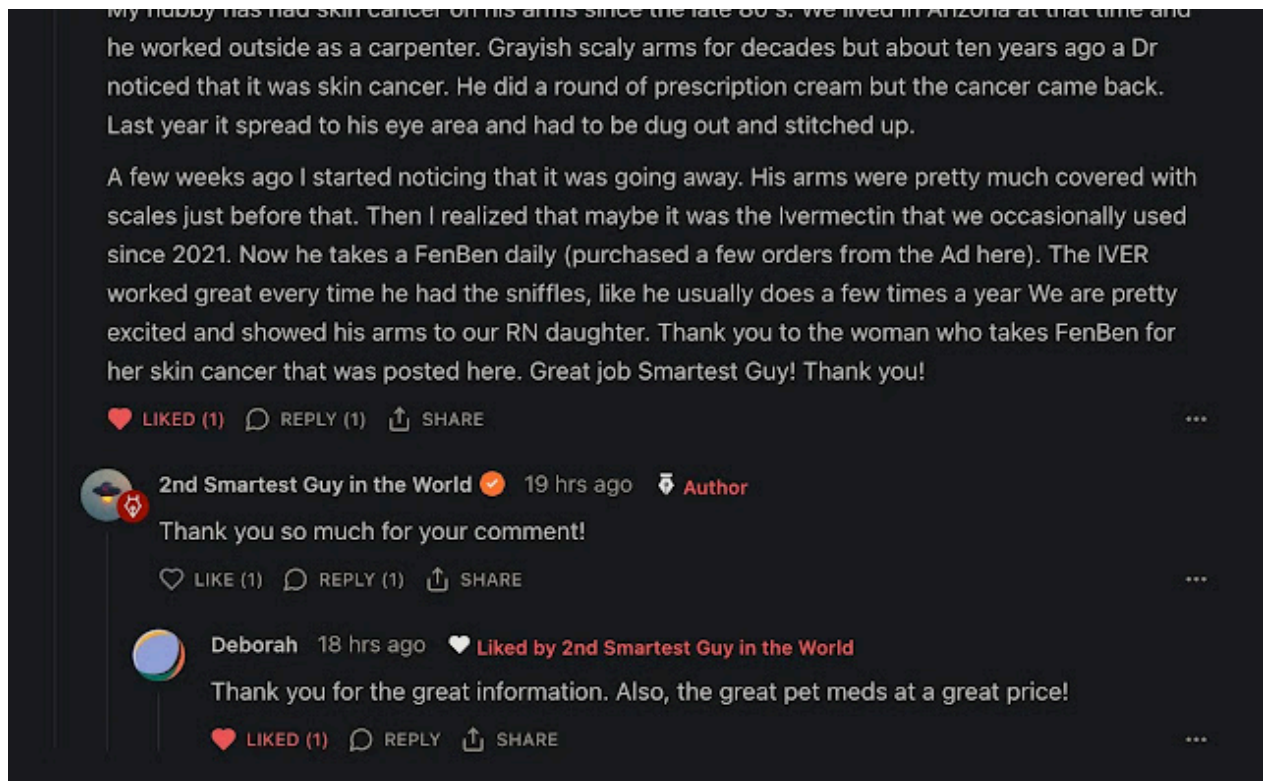
Result of FenBen Topical Treatment from September 25 through December 6, 2024

He writes,

“I’m still treating it once a day with Safeguard 10% Fenbendazole and it seems to still be improving. So I’m undecided about whether I need to have anything removed. I guess I’ll see how it goes over the next while. Maybe it’s deep into the tissue despite having improved the surface cells. No idea.”

Dr. Makis writes in response that patients who take matters into their own hands seem to do better.

**Case 5:**



source: <https://substack.com/home/post/p-155091883>

#### Case 4: Melanoma (Skin Cancer)

Shared by Dr William Makis (X/Twitter) - Last Edited: October 2024:

**FENBENDAZOLE** Testimonial in Stage 4 Melanoma Cancer patient - didn't listen to Oncologist's advice to stop Fenben, and is now cancer free.

There is a key lesson here. The Oncologist gave the opposite advice of what was good for the patient. That's because the Oncologist was following Cancer Guidelines set by Big Pharma (like Pfizer). If this patient had followed his Oncologist's advice and stopped the **Fenbendazole**, he would still have active Stage 4 melanoma metastases with a much worse prognosis. Maybe he'd already be dead. How do you know if you have a good Oncologist? Ask them how many COVID-19 Vaccines they took! The only correct answer is "0".



From: [REDACTED]  
To: William Makis

Mon, Sep. 9 at 9:37 a.m.

Dear Dr. Makis

Your posts are helping many, including my brother. [REDACTED] received a stage 4 melanoma diagnosis after his dermatologist biopsied a spot on his chest, "primary subdermal melanoma." It was planned for him to undergo surgery but changed the idea in favor of 2 types of infusions, every 3 weeks, beginning in June.

He underwent just 2, experiencing "knife-like" sensations to his mouth and tongue after his first, so bad that he could not eat. He was given steroids. His next infusion caused nausea and diarrhea, and given higher dose of steroids.

Because of your information and the Joseph Tippens story which I shared with him, [REDACTED] started Fenben prior to receiving any infusions, and continued with it despite his oncologist's caution to stop with it.

Because of the continued use of the steroids, his doctor halted the 3rd infusion and ordered a PET scan. I've attached [REDACTED] test results that my brother shared with me.

Thank you, Dr. Makis.

[REDACTED]

### Case 3: May, 2022 - Squamous Cell Carcinoma

In September 2021, I went to the cancer clinic to get my second PET scan done after receiving the news in March 2021 that I have been diagnosed with cancer, and learnt that day that my tumor has shrunk to half the size it first was. There were still signs of lymph nodes increasing or being classified as unknown results. I continued the use of the fenben protocol along with a whole bunch of other supplements to take on a daily basis, as within 5 months results improved in comparison to a whole year of fighting off the protocol before with little to non improvement in results. I strongly believe in this protocol and in case you wondered – I am not on any chemotherapy/radiation/immunotherapy or any other western medicine use – this is a full on natural and holistic journey I went on, and I am happy to share my current protocol with all cancer patients out there:

- Serrapeptase (at midnight)
- Vit D & K2, Tudca 500mg, Graviola 1ml (on an empty stomach)
- Varies supplementation with breakfast (like Vit C & B complex, probiotics, fish oil, curcumin, etc. along with fenben 888mg)
- Multi-vitamin, turkey tail extract, fenben 888mg, and B17 apricot seed (with dinner)
- Some more other supplements just before bed (like magnesium, Vit C, Graviola, high dose of melatonin, coffee enemas, etc)
- Detox baths (1 x week)
- Frequency music (before bed designed to kill cancer cells)
- Mainly following a plant-based diet
- Protein intake is limited to certain meats
- Fresh whole foods/vegetables
- Healthy fats only

Good luck.

### **Case 2: October, 2022**

In February and March of this year I was diagnosed with stage four melanoma. It had metastasized to my brain, lymph nodes, right lung, adrenal gland and right hip. My daughter pointed me to Joe's story and this site. I started taking the **fenbendazole** protocol even before my oncologist gave me her treatment plan using Immuno therapy. The oncologist said that it had about a 30% success rate but not to expect any great results on the first scan after 4 treatments.

I had a PET scan last week and the results were almost too good to be true. Cancer basically gone. The tumor in my right lung had shrunk to less than half the size it was on the first PET scan. The uptake on that tumor decreased from 19.9 to 2.6. I was told by her that an uptake of less than 4.0 is no longer considered as cancerous.

I have been on the **fenbendazole** protocol for 166 days now. I received 4 immunotherapy injections using 2 different drugs. I can't say for sure what definitively gave me these great results. Draw your own conclusions but I think the **fenbendazole** was largely responsible for the great results.

### **Case 1: January, 2022**

At first me and my partner were unsure about trying alternative treatments in addition to the radiation my partner receives. With the help from a holistic healer and referrals from a couple of people in our community, we found out about the **fenbendazole** protocol and started to add the protocol along with a few other supplements to my partner's daily intake/routine to aid in fighting the skin cancer on his neck.

## **27. Throat Cancer**

### **December, 2021**

I never knew that the day would surface for me to find out that I got diagnosed with cancer. My life turned upside down in seconds that day and ever since I have been doing research upon research – reading and gathering all the information I could get on the prognosis of my cancer and the treatments that are out there to help fight what is called HPV Squamous Cell Carcinoma (throat cancer). I ended up taking **fenbendazole** (dose of 2000mg) after a

## 28. Thymus cancer

October, 2022

Condition: Thymus cancer

Was diagnosed with Thymic Carcinoma 06/2022. Just finished week 8 of 12 week chemotherapy. I have been taking **fenbendazole**, curcumin, vit D & K, and CBD oil. We will do another PET scan in October and I fully expect the tumors to be completely gone or greatly reduced. Will update with the results asap. Blessings to all.

## 29. Tongue Cancer

Dr William Makis shared a case report on [X-Twitter](#) (Dec 2024):

IVERMECTIN & **FENBENDAZOLE** & Topical Ivermectin Testimonial - 70s year old US patient with Squamous Cell Carcinoma of Tongue seeing improvement - mainstream doctors coming on board!

I have a 70s year old US patient with a bad case of tongue cancer (squamous cell carcinoma)

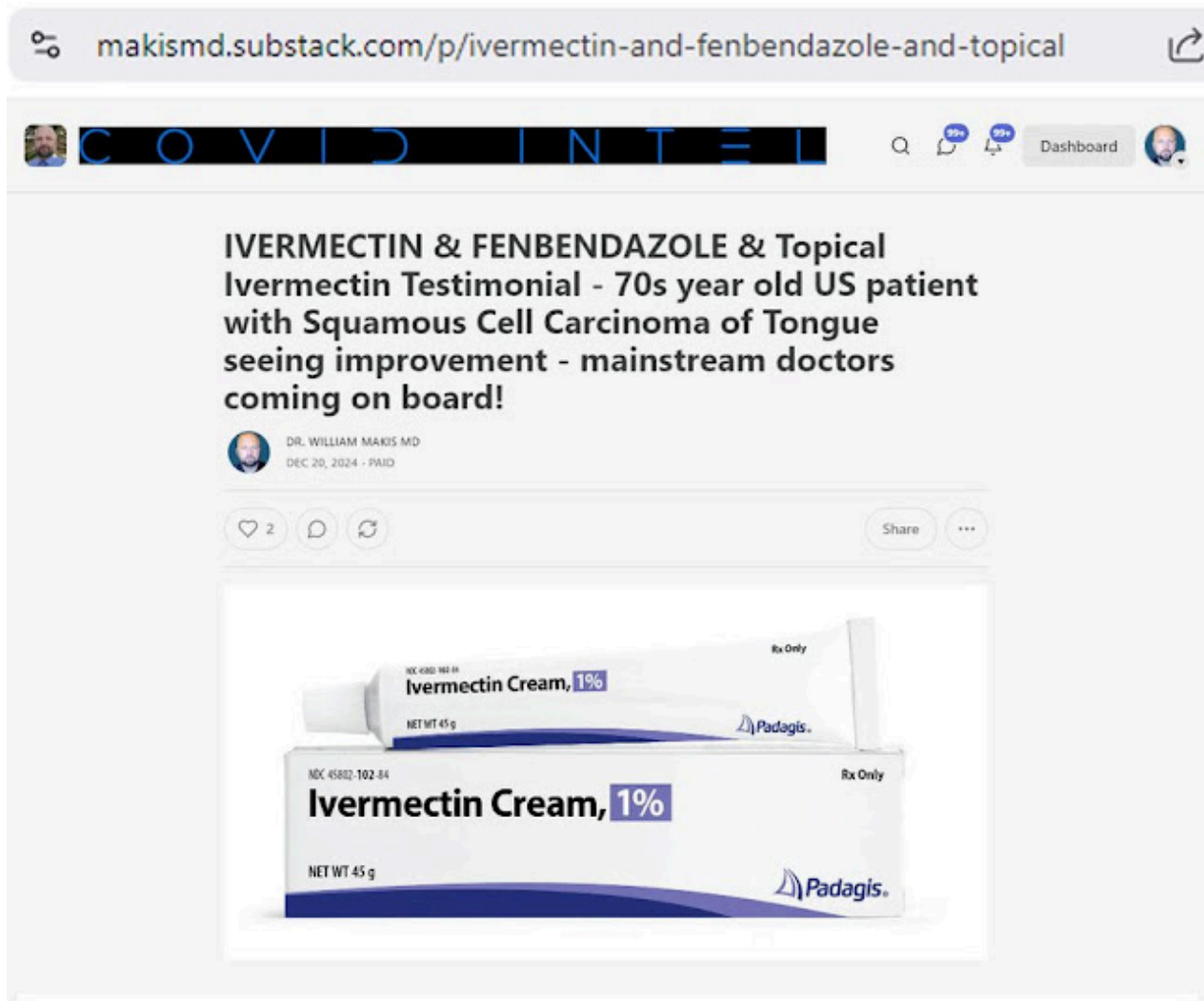
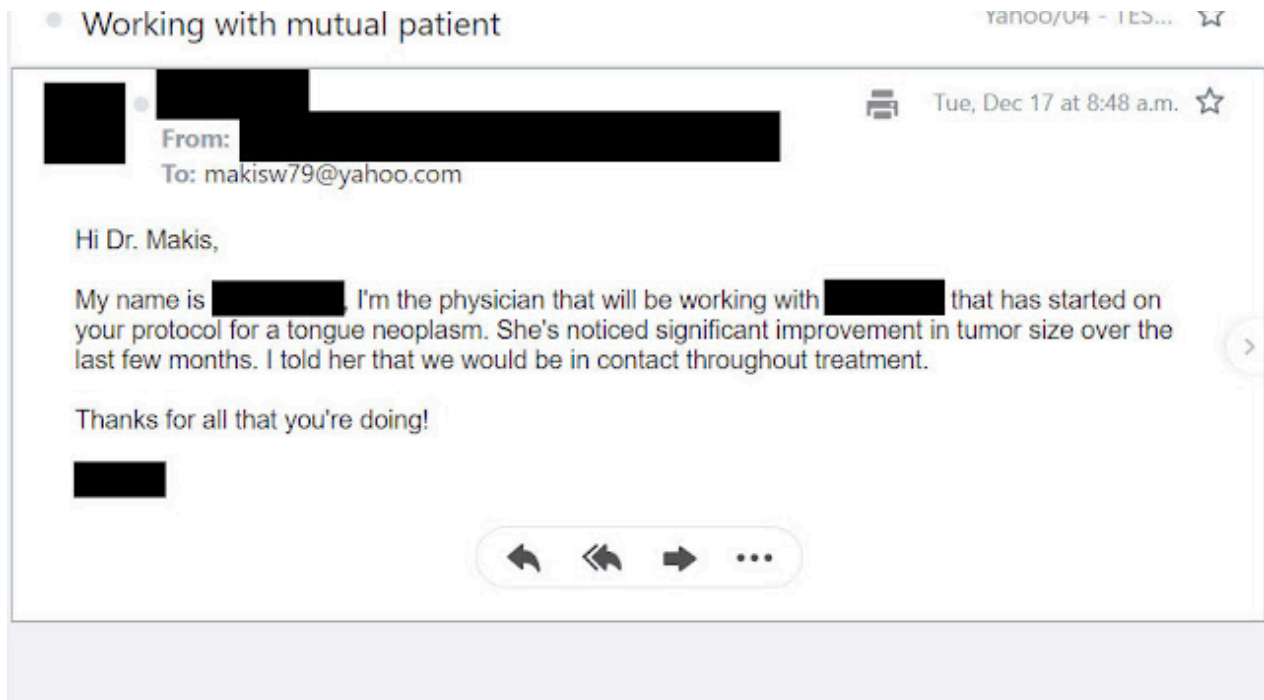Mainstream Oncology has offered to resect her tongue.

We started a high dose Ivermectin and **Fenbendazole** Protocol with one extra feature: topical Ivermectin cream applied twice a day.

Ivermectin 1mg/kg/day **Fenbendazole** 888mg/day Topical Ivermectin applied to tongue lesion twice a day

One of her physicians contacted me:

"started on your protocol for a tongue neoplasm...She's noticed significant improvement in tumor size of the last few months...we would be in contact throughout treatment...thanks for all that you're doing!"



## 30. Turbo Cancer, Fenbendazole and Ivermectin

Experts are seeing a puzzling rise in cancer in people under 50 that appears biologically different from late-onset cancers. While **some claim** cancer rates have been rising for decades and attribute the increase to sugary drinks, lifestyle, and sleep disruptions, others say mRNA COVID-19 vaccines have caused an emergence of “turbo cancers”—and U.S. regulatory agencies have not addressed the ever-growing problem.

Read More: [Ivermectin and Fenbendazole: Treating Turbo Cancer](#) - Dr William Makis

## 31. Uterine cancer

**May, 2023**

My 81 yo mother, Virginia, found out she had recurrent Endometrial Uterine Cancer back in Sept 2022. Stage 4 and Mets to abdominal area, lymph nodes, chest cavity and lungs. Radiation was not an option and she opted out of chemo, which would have only bought her a few extra months but would have made her very sick and weak. The doctor put her on a Hormone Blocker to keep it from growing any more. (But if in the lymph nodes, does it really stop it??) The Dr. sent her home to be under Hospice care for the remainder of her short time left on this earth.

I was not ready to accept this!! (Plus, my father has dementia and desperately needs her!) I prayed to God to give us wisdom and guidance. Within 24 hrs., three people approached me about the Joe Tippen Protocol, which I had never heard of at that time. I figured I might ought to listen so I googled and got sucked in! I started learning everything I could learn about it. Then I presented it to mom. She said, “Well, what do we have to lose!?!?”

So, in Oct, through prayer and God’s guidance, I got her up and running on “things” (FenBen, Tudca, Serrapetase, Tumeric, High-Dose Melatonin, Turkey Tail, Apricot Seeds, drinking Baking Soda water, and rubbing on Frankincense). She has been very weak this whole time so we weren’t sure if it was working or not. We planned her funeral, etc....

Then, 5 mo later, her Dr insisted she have another scan. She was very apprehensive but agreed. We (including the dr) were blown away by the results!!! The tumors are either gone or have shrunk considerably!!!! (All but ONE, which basically has stayed the same). All of the ascites (malignant fluid all in her Ab area) was GONE!! The Doctor patted himself on the back but WE PRAISE GOD AND FENBEN!!!

things are going well!!! (Other than her weakness)

\*UPDATE: I added her protocol as a picture so take notice for those interested.

A	B	C	D	E	F
<u>MEDICINE</u>	<u>DOSAGE</u>	<u>PURPOSE</u>	<u>ORDERED</u>	<u>MISC.</u>	<u>PRICE</u>
817 Apricot Seeds Capsules	1d	Fights against cancer	Amazon	"My Power Seeds"	\$55/6 mo.
Baking Soda	1 1/2 tsp./2d	Alkaline (Cut thru acid)	Walmart	S&S/6 mo.	.80/16 oz.
Curcumin Tumeric (UltraCur)	2x/d	Antioxidant, Anti-infl.	Pharmacy Plus in OK 580-795-7322		\$25.00/mo.
Frankincense Oil	3 drops 2-3x/d	Fights against cancer	Young Living	Rub on feet (bottoms)	\$104.00
Fenben (Dog DeWormer)	500mg/2d	Fights against cancer	Happy Healing Store		\$100.00
Hormone Therapy (Megastrol)	40mg/3d	Blocks hormone fed cancer	Walgreens		\$10.00
HiDose Melatonin	60mg/1d at night	Oxidation	Happy Healing Store		\$50.00
Serrapeptase	240,000 SPU/1d	Rids body of dead cancer cells	Amazon	S&S/5 wks.	\$16.00/2 mo.
Tudca	500mg/2d	Liver support (due to Fenben)	Amazon	S&S/8 wks.	\$27/mo.
Turkey Tail Mushroom	1000mg/2d	Immune System	Amazon	S&S/2mo.	\$23.00/mo.



January, 2023

Condition: Endometrial carcinoma

In May 2021 I was diagnosed with stage IV endometrial carcinoma. I went through 6 months

Zahara, and she recommended tweaking a few things and adding a few more supplements. I worked hard on my mindset and made sure I surrounded myself with positivity. I received the best news today I could hope for. No evidence of active disease. Never give up!

## Conclusion

Remember that these references are based on case reports, which provide preliminary evidence. For more comprehensive information, consider exploring additional research studies and clinical trials. Always consult with your healthcare provider/s before making any treatment decisions.

### Disclaimers:

- Please do not consider this guide as personal medical advice, but as a recommendation for use by professional providers. Consult with your doctor and discuss with her/him.
- Our aim here isn't to replace your doctors' advice. It is intended as a sharing of knowledge and information. Do take note that cancer is a continuous struggle between the immune system and the cancer cells. Cancer treatments are meant to assist the immune system in this battle.
- Cancer treatment should be part of a multi-modal approach in order to provide the best possible outcome. Diet and lifestyle changes are meant to run alongside conventional treatment. They are complementary, not alternative.
- Cancer care is a team effort with the patient at the centre. Care should be supervised and coordinated by a primary healthcare provider. Patients with cancer should consult with their regular oncologist as well as an integrative provider/oncologist, in addition to their primary care provider and the supporting nurses, dieticians and other allied healthcare professionals.
- While the term 'alternative' might imply opposition to conventional oncology, we prefer 'complementary,' 'integrated,' or 'holistic.' These terms better reflect the role of these strategies as part of a personalized value-added menu of strategies, ensuring the most effective and safe solutions for patients.

### Sources and References:

- **FENBENDAZOLE and CANCER - at least 12 Anti-Cancer Mechanisms of Action** - Dr William Makis
- **Targeting the Mitochondrial-Stem Cell Connection in Cancer Treatment: A Hybrid Orthomolecular Protocol**

## Find Integrative Oncologists in USA, Mexico, Europe or Asia

While the potential anti-cancer properties of [fenbendazole](#) are intriguing, it's crucial to approach with caution.

Consulting with an integrative healthcare expert is key to crafting a [Fenbendazole](#) protocol tailored to your unique health requirements.

To find integrative oncologists, check out "[find integrative oncologists](#)".

### Related:

[Mebendazole vs fenbendazole for cancer](#)

[Ivermectin vs Fenbendazole for Cancer](#)

[Top 18 Repurposed Drugs and Metabolic Interventions to Control Cancer](#)

[High dose IV vitamin C for cancer treatment](#)

[CAR-T vs CAR-NK - The Cancer Cell Therapy Showdown](#)

[Joe Tippens Protocol Fenbendazole](#)

[Ivermectin and Fenbendazole: Treating Turbo Cancer](#)

[Fenbendazole: Questions Answered, Things to Know, Useful Tips](#)

### New & Improved Joe Tippens Protocol

In 2016, Joe Tippens was diagnosed with non-small-cell lung cancer with extensive metastatic disease. At the advice of a veterinarian friend, he took [Fenbendazole](#) together with [nanocurcumin](#), and three months after starting these drugs his PET scan was completely clear.

Dr. William Makis.

- **Fenbendazole** is commonly taken at 300 mg for six days a week, with doses increasing to up to 1 gram in cases of aggressive "turbo cancers." The original Joe Tippens protocol recommended the **Panacur C** brand of **fenbendazole**.
- **Ivermectin** (24 mg, 7 days a week) or in the case of severe turbo cancers up to 1mg/kg/day.
- Lifestyle: Eliminate sugar (**BMJ 2023**), adopt a whole-food diet, avoid ultra-processed foods (**BMJ 2024**), prioritize sleep, and manage stress.
- **Bio-Available Curcumin** (600mg per day, 7 days a week).
- **Vitamin D** (62.5 mcg [2500 IU] seven days a week).
- **Enhanced absorption Berberine** (500mg per day) if you are trying to starve your cancer of sugars.

Please note that this protocol now includes the vital Vitamin D addition, with the one day off for the **fenbendazole** administration. This protocol represents the most comprehensive and cutting edge repurposed drug and vitamin treatment approach to date.

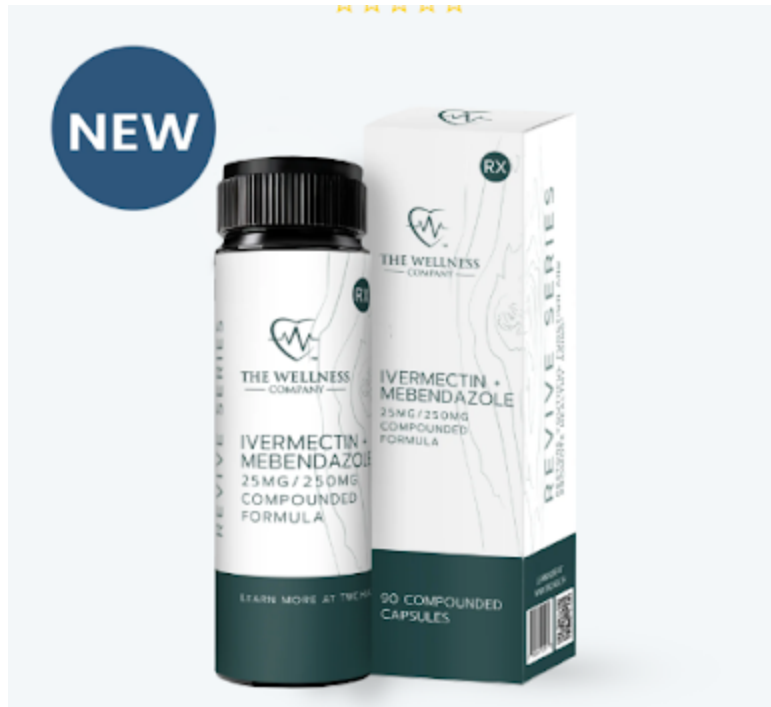\*Note: If you are taking ivermectin and mebendazole, you might not need **fenbendazole**. Consult your doctor.

- Vitamin E: Removed from the protocol (**Joe Tippens, July 22, 2020**) due to interactions (e.g., with blood thinners).

**Source:** Adapted from OneDayMD.com. <https://www.onedaymd.com/2024/11/fenbendazole-and-cancer-15-minutes-with.html> (November 2024).

Read More: This article is part of the *Winning the War on Cancer* series.

### **The Wellness Company's Ivermectin and Mebendazole**



Ivermectin and mebendazole, both approved for human use, are now available in the U.S.

Researched and approved by Dr. Peter McCullough.

- Prescribed by licensed medical professionals
- Compounded and dispensed by a licensed US-based pharmacy
- Approved for human use

**Where to buy Ivermectin and Mebendazole Formula:** Available on *The Wellness Company's* website. Here is the link: [Ivermectin and Mebendazole](#).



cancer

case studies

fenbendazole

repurposed drugs

winning the war on cancer



Enter Comment

- [Home](#)
- [About Us](#)
- [Contact Us](#)
- [Find a Medical Specialist](#)
- [Privacy Policy](#)

Labels ▼

Archive ▼

Popular posts from this blog

### Ivermectin and Fenbendazole: Treating Turbo Cancer - Dr William Makis

By Editorial Team - *March 18, 2025*



Ivermectin Resources Recently, I have seen tremendous demand for some sort of initial guidance “WHERE TO START” with High Dose Ivermectin for CANCER. I have two articles and a Video that go into depth: Ju ...

[READ MORE](#)

### Fenbendazole Joe Tippens Protocol: A Step-by-Step Guide (2025)

By Editorial Team - *March 09, 2025*



If you have been diagnosed with cancer, or have a loved one that is suffering from cancer, chances are you have heard about the Joe Tippens Cancer Protocol. The Fenbendazole Cancer Protocol has been gaining ...

[READ MORE](#)

By Editorial Team - *March 14, 2025*



We are pleased to announce that the first-of-its-kind protocol utilizing Ivermectin, Mebendazole, and **Fenbendazole** for cancer treatment has been peer-reviewed and officially published on September 19, 2024. ...

[READ MORE](#)

## **Fenbendazole: Questions Answered, Things to Know, Useful Tips - Ben Fen**

By Editorial Team - *January 04, 2025*




Readers ask a variety of questions regarding the use of **fenbendazole**. This article is mainly a result of those questions and has been in the hopper for quite a while. It is long overdue as it contains items of importa ...

[READ MORE](#)

## **Fenbendazole vs Mebendazole for Cancer: What is the Difference?**

By Editorial Team - *March 21, 2025*



What is **fenbendazole** used for in humans? **Fenbendazole** (also known as fenben) is a veterinary medication used to treat parasites and worms such as tapeworms, hookworms, roundworms, and whipworms, in a ...

[READ MORE](#)

## **Best Ivermectin Dosage for Humans with Cancer or Different Cancer Types (2024)**

By Editorial Team - *December 21, 2024*

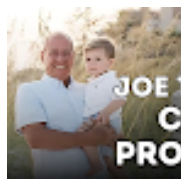

Introduction This article discusses dosage considerations and key factors regarding the use of ivermectin in cancer treatment. Commonly available information about ivermectin dosages is often inaccurate whe ...

[READ MORE](#)

## FENBENDAZOLE and CANCER: 15 Minutes with Dr. William Makis

By Editorial Team - February 05, 2025



Transcription (emphasis 2SG - 2nd Smartest Guy): Hi, everyone. Welcome to another episode of 15 minutes with Dr. Makis, my new hard hitting medical podcast. This episode is about fenbendazole and cancer. I w ...

[READ MORE](#)

## 12 Types of Zinc Supplementation and Absorption 2025

By Editorial Team - January 27, 2025



Zinc is a powerful immune nutrient known for its benefits for providing immune health support and anti inflammation as well as for improving cold and respiratory symptoms, wound healing, acne reduction, and ...

[READ MORE](#)

## Fenbendazole: Side Effects, Safety and Dosage in Humans (2025)

By Editorial Team - December 31, 2024



Fenbendazole is a broad spectrum anthelmintic used against gastrointestinal parasites including: giardia, roundworms, hookworms, whipworms, the tapeworm genus Taenia (but not effective aga ...

[READ MORE](#)

 Powered by Blogger

Copyright © 2013 - 2025 · OneDayMD.com · All Rights Reserved



